

ORIGINAL ARTICLE

Interventional

Primary Aspiration Technique in Endovascular Stroke Treatment

Lukas Meyer¹, Maria Politi¹, Maria Alexandrou¹, Christian Roth¹, Freimuth Brunner²,
Andreas Kastrup², Panagiotis Papanagiotou^{1,3}

¹ Clinic for Diagnostic and Interventional Neuroradiology, Hospital Bremen-Mitte, Germany

² Clinic for Neurology, Hospital Bremen-Mitte, Germany

³ Neuroscience and Vascular Simulation Unit, Anglia Ruskin University, Essex, UK

SUBMISSION: 8/2/2017 | ACCEPTANCE: 5/4/2017

ABSTRACT

Purpose: To investigate the safety and efficacy of “Primary Aspiration Technique” as an initial approach for intracranial artery occlusions in treatment of acute ischaemic stroke.

Material and Methods: A total of 107 patients with acute large intracerebral artery occlusions located in the anterior or posterior circulation were included in the study. All the patients were treated with “Primary Aspiration Technique” by using either the Penumbra ACE or the ACE 64 aspiration catheter (Penumbra Inc.). Recanalisation results were assessed by follow-up angiography immediately after the procedure. Neurological evaluation using the National Institutes of Health Stroke Scale and modified Rankin Scale (mRS) was performed on admission and at discharge.

Results: “Primary Aspiration Technique” alone was successfully used in 65% of the cases. The overall recanalisation rates were achieved in 88.8% of the cases.

In 37 of the 107 cases (35%) secondary stent retriever devices were used in addition. If primary aspiration was successful, the median time from groin puncture until final recanalisation was 32 minutes.

An early good clinical outcome at discharge (mRS ≤ 2) was seen in a total of 50 patients (47%). In-hospital mortality was 15% (16/107). 58.6% (41/70) of the patients achieved an early good clinical outcome (mRS ≤ 2) when primary aspiration technique was successful.

By performing primary aspiration in different vessels the chance of receiving a Thrombolysis In Cerebral Infarction score $\geq 2b$ in the middle cerebral artery was 2.3 times higher than in the terminal internal carotid artery.

Conclusions: “Primary Aspiration Technique” is a safe and effective endovascular thrombectomy method. The main advantages of aspiration technique are the fast procedure time and the high rate of favourable clinical outcome if primary aspiration is successful.



CORRESPONDING
AUTHOR,
GUARANTOR

Panagiotis Papanagiotou, MD, Ph.D, Director, Clinic for Diagnostic and Interventional Neuroradiology, Hospital Bremen-Mitte, Germany, Neuroscience and Vascular Simulation Unit, Anglia Ruskin University, Essex, UK
E-mail: papanagiotou@me.com



KEY WORDS

acute ischaemic stroke; mechanical thrombectomy; aspiration

1. Introduction

Acute ischaemic stroke is the number one cause of disability and one of the most common causes for dementia and death in the developed world [1]. Thus, in recent years a lot of effort has been made to develop new revascularisation devices that provide faster and higher recanalisation rates in order to generate a better clinical outcome for patients. Based on 5 positive multicenter randomised clinical trials, the endovascular therapy has undergone a revolution [2-6]. One of the main changes in these positive studies was the utilisation of stent retriever devices [7]. After this major breakthrough in mechanical thrombectomy, the stent retriever has proved to be a safe method with high recanalisation rates [8-12]. However, clinical experience has been reported on situations that are resistant to stent retriever recanalisation attempts. These situations include especially occlusions located in terminal internal carotid artery (tICA) and middle cerebral artery (MCA) bifurcation and trifurcation thrombi, as well as hard thrombi configuration [10].

The aspiration technique has been an early hallmark in the history of mechanical thrombectomy and its utility has been demonstrated in a large number of trials and clinical experiences with positive results [13, 14]. In the course of time, a great effort has been made to develop new aspiration devices, including changes in the distal inner diameters of the catheter. We report on our results with the aspiration catheters Penumbra ACE (0.060" distal inner diameter) and ACE64 (0.064" distal inner diameter) (Penumbra Inc.) using the "Aspiration Technique" as a primary approach for intracranial artery occlusion.

2. Material and Methods

2.1 Study population

Between January 2014 and December 2015, 350 patients with an acute ischaemic stroke were treated endovascularly in our department. We retrospectively collected and analysed these cases in which "Primary Aspiration Technique" was used. "Primary Aspiration Technique" with the aspiration catheters Penumbra ACE or ACE64 (Penumbra Inc.) was used in 107 of 350 cases (30.5%).

Neurological evaluation was performed using the Na-

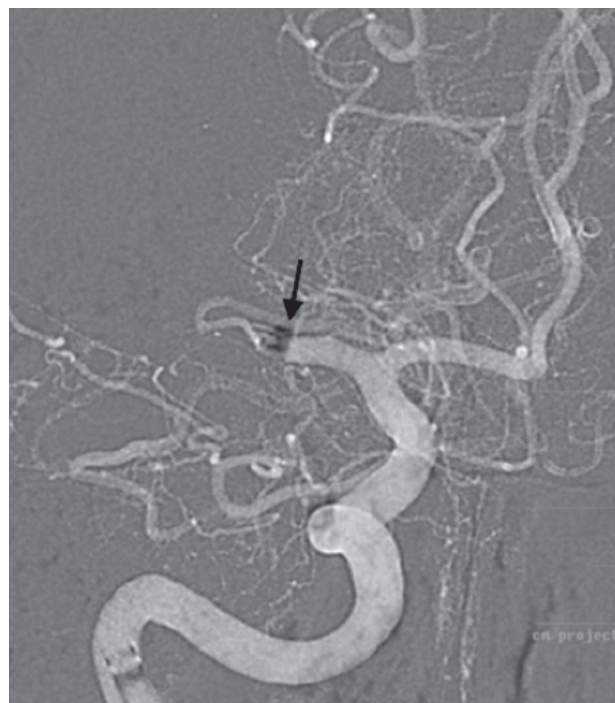


Fig. 1. MCA occlusion with placement of the aspiration catheter on the occlusion site (arrow)

tional Institutes of Health Stroke Scale (NIHSS) and modified Rankin Scale (mRS) on admission and at discharge. Computed tomography (CT) and CT angiography were performed on admission in order to rule out intracranial haemorrhage (ICH) and to assess vessel occlusions. A CT control scan was obtained before discharge or if the patient's symptoms worsened.

If a large vessel occlusion was found eg. occlusion in the M1 or M2 segment of the MCA, internal carotid artery (ICA), or in the basilar artery, treatment was started with IV tPA, provided the patients were eligible within 4.5 h after symptom onset. Patients were then transferred for interventional treatment. Patients were treated under consensus sedation. Uncooperative patients were treated under general anaesthesia with intubation and ventilation.

2.2 "Primary Aspiration Technique"

After placement of a 6F sheath, the target vessel was navigated with a 0.014" microwire, a microcatheter, and the

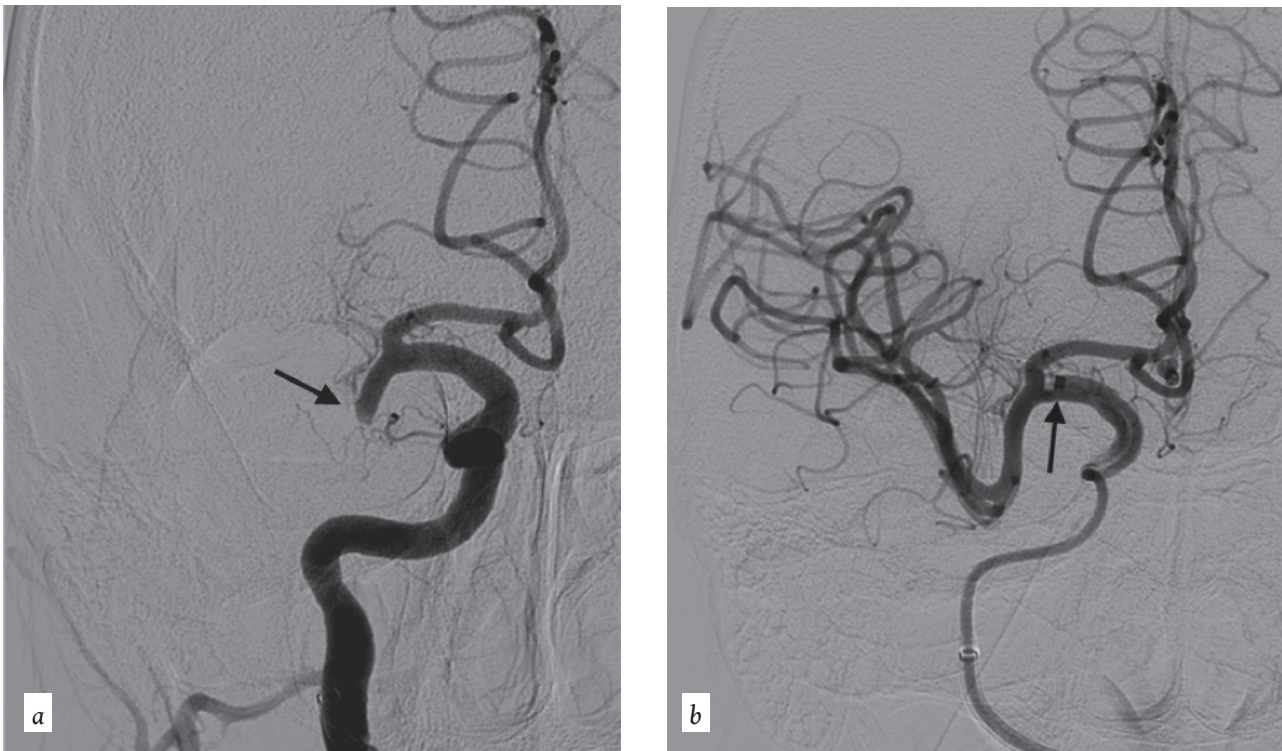

Fig. 2. MCA occlusion (2a-arrow), successful recanalisation after aspiration with Penumbra ACE catheter (2b-arrow)

aspiration catheter. The thrombus was passed with the microwire and microcatheter, and the aspiration catheter was placed directly in the proximal part of the thrombus. The microwire and the microcatheter were then removed. Entrapment of the thrombus was indicated by the absence of backflow. The catheter was then retrieved with constant negative pressure to avoid loss of thrombus. After each retrieval of clot fragments, the procedure was repeated until a Thrombolysis In Cerebral Infarction (TICI) score of ≥ 2 or 3 was reached [10] (Fig. 1 & Fig. 2). The ACE catheter was used in the first cases and following commercial availability, ACE 64 was used in all next cases. A total 49% of the patients were treated with ACE and 42% of the patients with ACE 64. In 9% of the cases the aspiration catheter that was used could not be retrospectively identified.

Secondary stent retriever devices (pRESET - Phenox inc. or Catch Plus- Balt inc.) were used additionally in cases where a TICI 2b or 3 recanalisation was not successful with the aspiration technique, either due to partial or no recanalisation or due to distal embolisation in the M2-M3 branches of the MCA, or anterior cerebral artery for anterior circulation and posterior cerebral artery for posterior circulation.

2.3 Evaluation

Functional outcome was assessed by two senior vascular neurologists certified for NIHSS and modified Rankin Scale (mRS) scoring (AK; FB). The mRS at the time of hospital discharge was used for early clinical outcome analysis. A favourable early clinical outcome (mRS of 0-2 at the time of discharge) was the primary outcome measure. Secondary outcome measures included in-hospital death, symptomatic ICH, defined as worsening of the patient's neurological status of more than 4 on the NIHSS scales, time from groin puncture to recanalisation, recanalisation of the occluded target vessel measured by the TICI score. The analysis also included evaluation of the two aspiration catheters.

2.4 Statistical Methods

Standard descriptive statistics were employed for endpoint study parameters. The non-parametric Wilcoxon signed-rank test was used to prove significance of the clinical outcome (mRS) between hospitalisation and discharge. The Fisher's exact test was used for categorical variables (mortality, procedural complications) in comparing both catheters (ACE vs. ACE64). Continuous parameters (TICI, mRS, Time of Intervention)

Table 1: Patients' baseline characteristics

Characteristics	All patients (n=107)	Successful primary aspiration (n=70)	Additional stent retriever (n=37)
Age (years) (median (range))	74 (24-95)	72.5 (24-95)	76 (45-93)
Male sex (%(n))	44.9 (48/107)	44.3 (31/70)	45.9 (17/37)
Baseline NIHSS (median (range))	15 (1-29)	13.5 (1-24)	16 (4-29)
mRS at hospitalisation (median (range))	5 (1-5)	4 (1-5)	5 (3-5)
IVT* (%(n))	45.8 (49)	51.4 (36/107)	35.1 (13/37)
Catheter model (%(n))	ACE: 48.6% (52/107) ACE64: 42.1% (45/107) Unknown: 9.3% (10/107)	ACE: 44.3% (31/107) ACE64: 51.4% (36/107) Unknown: 4.3% (3/107)	ACE: 56.8 (21/37) ACE64: 24.3 (9/37) Unknown: 18.9 (7/37)
Location:			
Anterior circulation			
MCA M1 (%(n))	52.3 (56/107)	57.1 (40/70)	43.2 (16/37)
MCA M2 (%(n))	6.5 (7/107)	8.6 (6/70)	2.7 (1/37)
tACI (%(n))	26.2 (28/107)	21.4 (15/107)	35.1 (13/37)
Posterior circulation			
VA (%(n))	1.9 (2/107)	2.9 (2/107)	-
BA (%(n))	12.1 (13/107)	8.6 (6/107)	18.9 (7/37)
PCA (%(n))	0.9 (1/107)	1.4 (1/107)	-

*IVT=intravenous thrombolysis

were compared by using the Mann-Whitney U test for non-normally distributed data. The odds ratio was calculated to measure the association between occlusion site and successful Primary Aspiration, as well as the association of catheter models and efficacy of Primary Aspiration in different vessels. All statistical analyses were performed by using SPSS V. 22 (SPSS Inc., Chicago, IL, USA). Significance level was set at $\alpha=0.05$.

3. Results

3.1 Patient population

The 107 patients were selected from 350 patients with acute ischaemic stroke and an intracranial large vessel oc-

clusion that were treated by mechanical thrombectomy at our institution. Median age of the patients was 74 years (24-95) and 55% (59/107) were women. 46% (49/107) of the patients received intravenous thrombolysis with a standard dose (0.9 mg/kg) in addition. The patients had a median NIHSS score on admission of 15 (range: 1-29). Vessel occlusions were located in the anterior circulation in 85% of the cases with M1 in 52% (56/107), M2 in 7% (7/107), and tICA 26% (28/107). Within the posterior circulation, occlusions were located at the vertebral artery (VA) in 1.9% of cases (2/107), basilar artery (BA) in 12% of cases (13/107), and in the P1 segment of posterior cerebral artery (PCA) in one case. **Table 1** provides an overview of the patients' baseline characteristics.

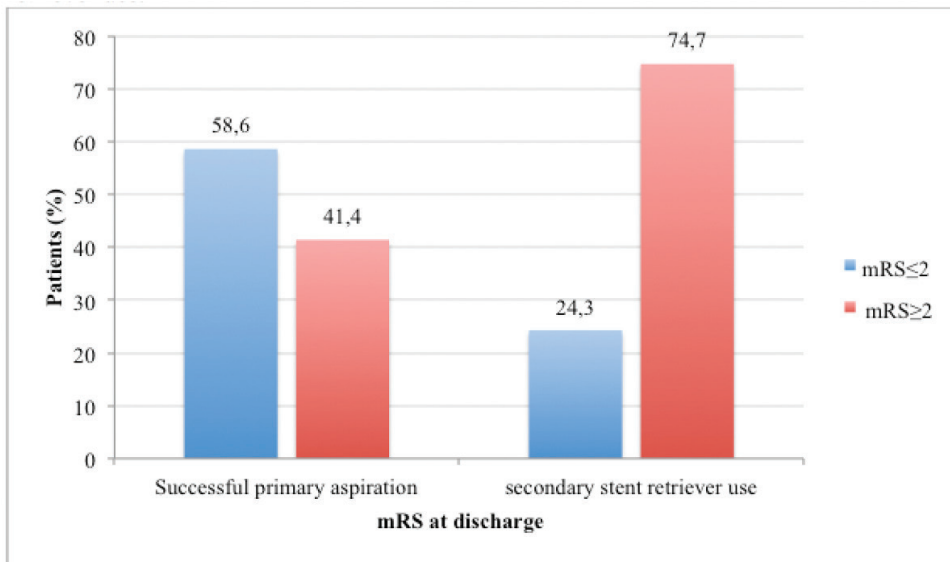


Fig. 3. mRS at discharge in cases with successful primary aspiration and secondary stent retriever use

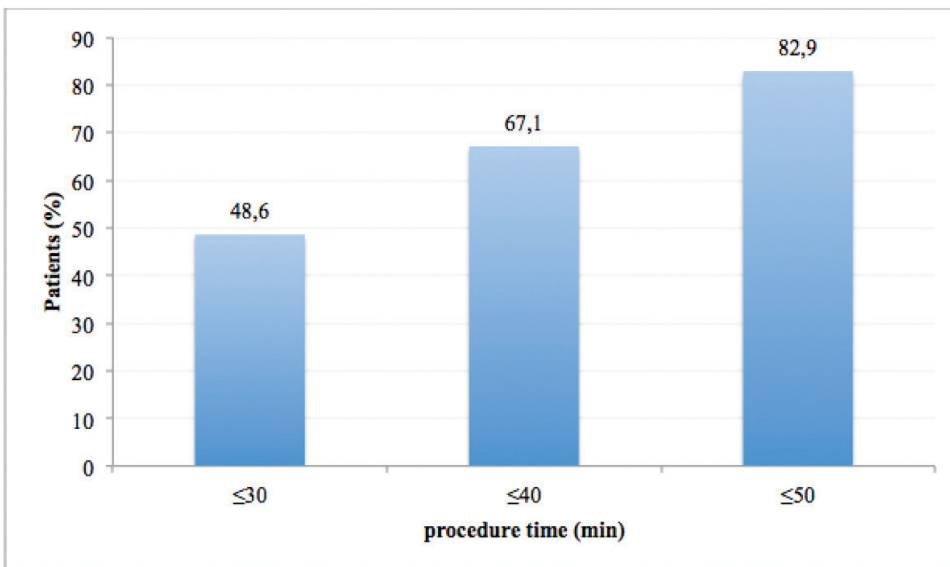


Fig. 4. Successful primary aspiration (n=70) - time from groin puncture to recanalisation in 3 time groups

3.2 Clinical Outcome

Early good clinical outcome at discharge (mRS ≤2) was seen in a total of 50 patients (47%). In-hospital mortality was 15% (16/107). In the group of patients in which primary aspiration technique was successful, leading to a TIC1 score 2b/3, 58.6% (41/70) achieved an early good clinical outcome. The mortality rate in this group was 7% (5/70) and there were no symptomatic intracerebral haemorrhages. If the primary aspiration was not successful, only 24.3% of the patients achieved a good clinical outcome (Fig. 3). The median baseline NIHSS was 12 in the group of patients (41/70) with good clinical outcome (mRS ≤2). Patients (29/70) with an mRS ≥2 showed a median baseline NIHSS of 17.

3.3. Angiographic Outcome

Successful recanalisation rates (defined as TIC1 ≥2b) were achieved in 88.8% of the cases. In 65% (70/107) the primary aspiration alone was used successfully. There were 37/107 (35%) cases in which secondary stent retriever devices had been used in addition. The reasons for secondary use of stent retriever devices after primary aspiration were either partial or no recanalisation, or distal embolisation.

For all the patients, median time from groin puncture until final recanalisation result was 41 minutes (range 16–105). If primary aspiration was successful, the median time from groin puncture until final recanalisation was 32 minutes. Moreover, in this group 48.6% of the pro-

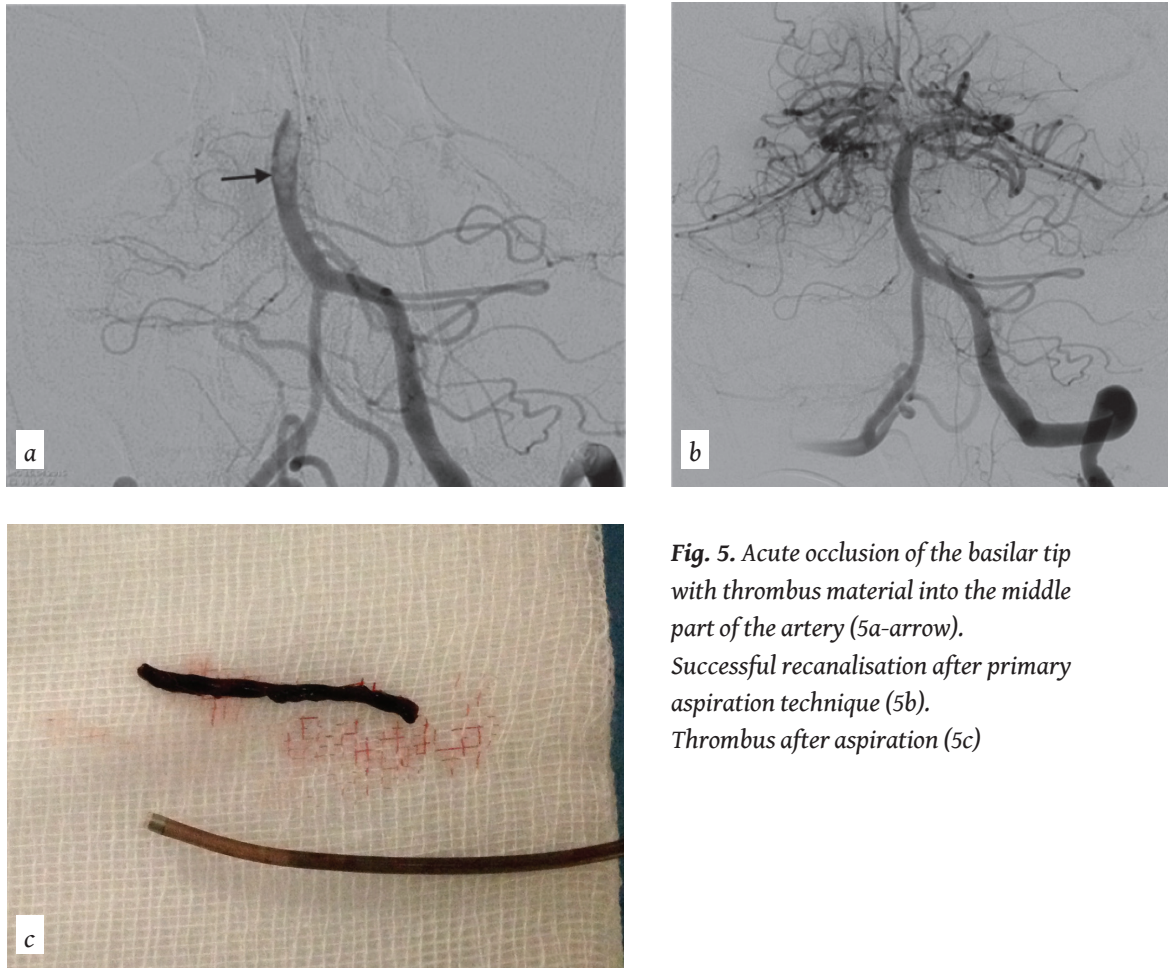


Fig. 5. Acute occlusion of the basilar tip with thrombus material into the middle part of the artery (5a-arrow). Successful recanalisation after primary aspiration technique (5b). Thrombus after aspiration (5c)

cedures were successful within 30 min and 82.9% within 50 min (Fig. 4).

All patients initially received mechanical thrombectomy with the “Primary Aspiration Technique” by using one of the two aspiration catheters. In 49% (52/107) of the cases the Penumbra ACE (0.060” distal inner diameter) was used and after Penumbra ACE64 (0.064” distal inner diameter) was available, ACE64 was used in 42% of the cases (45/107). In 9% (10/107) of the cases retrospective classification of the catheter model was not possible. There was no significant difference between the two catheter models in terms of clinical parameters and endpoints. However, mortality with the ACE64 was lower, 7% (3/45), than with the ACE 17% (9/52; $p=0.133$).

In the analysis of cases with secondary stent retriever use, the ACE showed a significantly ($p<0.002$) higher amount of partial recanalisation than no recanalisation after performing primary aspiration. By analysing the efficacy of the “Primary Aspiration Technique” in occlu-

sions of the two most frequent blood vessels (tICA, MCA) there was a 2.3 higher chance of receiving a TICI $\geq 2b$ in the MCA than in the tICA, however this finding was not statistically significant ($p=0.072$). Comparing the ACE and ACE64 there was 4.0 higher chance of receiving a TICI $\geq 2b$ in the MCA with the ACE64 than with the ACE, this finding was also not statistically significant ($p=0.053$). There was no difference in either using the ACE64 or ACE in the tICA.

4. Discussion

Based on recent positive multicenter randomised clinical trials, endovascular stroke treatment has undergone a revolution. One of the main changes in these positive studies was the utilisation of stent retriever devices. However, clinical experience has reported situations that are resistant to stent retriever recanalisation attempts. These situations include occlusions located in terminal ICA and MCA bifurcation and trifurcation thrombi, as

well as hard thrombi configuration. For these cases, direct aspiration of the thrombus can be used as an alternative technique. Over the last few years new aspiration devices were developed, including changes in the distal inner diameters of the catheter, therefore the “Aspiration Technique” is in some centers used as a primary approach for intracranial artery occlusion.

This retrospective study demonstrates the efficacy and safety of “Primary Aspiration Technique” for mechanical recanalisation in patients with a large intracranial vessel occlusion. The main findings are a high rate of favourable early clinical outcome with mRS score 0-2 at discharge (47%) with a low rate of mortality (15%).

These results are comparable with those of thrombectomy in which stent retrievers were used with mRS score 0-2 46% at 90 days and mortality 15.3% in a recently published meta-analysis of five randomised clinical trials [15]. The rate of symptomatic intra-cerebral haemorrhage was in the present study 1.9%, slightly lower compared to the rate of 4.4% in the above meta-analysis. If we compare the present study of primary aspiration technique to our own analysis of 270 patients receiving endovascular treatment with stent retrievers in everyday clinical practice, we see in similar population (median NIHSS 14 compared to 15 in the present study) a 10% difference in favourable early clinical outcome (mRS 0-2 at discharge 47% vs. 37%) [16].

Another important finding is that patients in whom primary aspiration led directly to recanalisation without secondary use of stent retrievers had a high rate of good clinical outcome (58.6%). Moreover, procedure time was fast, about 50% of the procedures being successful within 30 min and 82.9% within 50 min. However, only in 65% of the cases was primary aspiration successful on its own. In 35% of cases secondary stent retriever devices had been used in addition, due to no recanalisation with aspiration or due to distal embolisation. In these cases, the clinical outcome was favourable only in 24.3% of the patients. These results suggest that, if primary aspiration technique is used, the goal should be the high rate of direct recanalisation with the aspiration device [17]. New generations of aspiration catheters with a larger distal in-

ner diameter and improved aspiration techniques could lead to higher rates of successful primary aspiration, resulting to better clinical outcome.

By analysing the efficacy of the “Primary Aspiration Technique” in occlusions of the two most frequent blood vessels (tICA, MCA) there was a 2.3 higher chance of receiving a TICI $\geq 2b$ in the MCA than in the tICA. These results are not statistically significant, probably due to small sample size. This finding seems logical since the MCA has a smaller vessel diameter compared to tICA, which makes successful thrombus aspiration easier in MCA than in tICA. On the other hand, our study shows that catheters with a larger distal inner diameter (ACE 64, 0.064” inner diameter) were more effective compared to catheters with a smaller inner diameter (ACE, 0.060” inner diameter) to recanalise the occluded vessel (Fig. 5). The above results suggest that the size of the occluded vessel and the inner diameter of the aspiration catheter may influence aspiration efficacy. Since thrombectomy, and especially aspiration, catheters are continually improving, better results can be expected for catheters with a larger inner diameter.

The first limitation of the present study is its retrospective analysis. The second is that it describes evolving treatment, especially over the past few years, with an enormous advancement in the field of intracranial recanalisation techniques and devices.

In conclusion, our study suggests that “Primary Aspiration Technique” is a safe and effective endovascular thrombectomy method with clinical results comparable to those of stent retriever devices. The main advantages of aspiration technique are the fast procedure time and the high rate of favourable clinical outcome if primary aspiration is successful. **R**

Conflict of interest:

Papanagiotou P:

- Local Pi Swift Prime Study (Medtronic Inc.)
- Consultancy Penumbra Inc. Johnson & Johnson, Phenox Inc.

Roth C: Consultancy Penumbra Inc., Phenox Inc.

REFERENCES

1. Rothwell PM, Coull AJ, Silver LE, et al. Population-based study of event-rate, incidence, case fatality, and mortality for all acute vascular events in all arterial territories (Oxford Vascular Study). *Lancet* 2005; 366: 1773-1783.
2. Saver JL, Goyal M, Bonafe A, et al. Stent-retriever thrombectomy after intravenous t-PA vs. t-PA alone in stroke. *N Engl J Med* 2015; 372: 2285-2295.
3. Goyal M, Demchuk AM, Menon BK, et al. Randomized assessment of rapid endovascular treatment of ischemic stroke. *N Engl J Med* 2015; 372: 1019-1030.
4. Jovin TG, Chamorro Á, Cobo E, et al. Thrombectomy within 8 hours after symptom onset in ischemic stroke. *N Engl J Med* 2015; 372: 2296-2306.
5. Berkhemer OA, Fransen PSS, Beumer D, et al. A randomized trial of intraarterial treatment for acute ischemic stroke. *N Engl J Med* 2015; 372: 11-20.
6. Campbell BCV, Mitchell PJ, Kleinig TJ, et al. Endovascular therapy for ischemic stroke with perfusion-imaging selection. *N Engl J Med* 2015; 372: 1009-1018.
7. Spiotta AM, Chaudry MI, Hui FK, Turner RD, Kellogg RT, Turk AS. Evolution of thrombectomy approaches and devices for acute stroke: A technical review. *J Neurointerv Surg* 2015; 7: 2-7.
8. Grunwald IQ, Walter S, Papanagiotou P, et al. Revascularization in acute ischaemic stroke using the penumbra system: The first single center experience. *Eur J Neurol* 2009; 16: 1210-1216.
9. Papanagiotou P, Roth C, Walter S, et al. Treatment of acute cerebral artery occlusion with a fully recoverable intracranial stent: A new technique. *Circulation* 2010; 121: 2605-2606.
10. Papanagiotou P, White CJ. Endovascular reperfusion strategies for acute stroke. *JACC Cardiovasc Interv* 2016; 9: 307-317.
11. Roth C, Papanagiotou P, Behnke S, et al. Stent-assisted mechanical recanalization for treatment of acute intracerebral artery occlusions. *Stroke* 2010; 41: 2559-2567.
12. Roth C, Reith W, Walter S, et al. Mechanical recanalization with flow restoration in acute ischemic stroke: The ReFlow (mechanical recanalization with flow restoration in acute ischemic stroke) study. *JACC Cardiovasc Interv* 2013; 6: 386-391.
13. Penumbra Pivotal Stroke Trial Investigators. The penumbra pivotal stroke trial: Safety and effectiveness of a new generation of mechanical devices for clot removal in intracranial large vessel occlusive disease. *Stroke* 2009; 40: 2761-2768.
14. Turk AS, Spiotta A, Frei D, et al. Initial clinical experience with the ADAPT technique: A direct aspiration first pass technique for stroke thrombectomy. *J Neurointerv Surg* 2014; 6: 231-237.
15. Goyal M, Menon BK, van Zwam WH, et al. Endovascular thrombectomy after large-vessel ischemic stroke: A meta-analysis of individual patient data from five randomised trials. *Lancet* 2016; 387: 1723-1731.
16. Kastrup A, Brunner F, Wasser K, et al. Endovascular therapy vs. thrombolysis in patients with anterior circulation stroke in everyday clinical practice. *Int J Stroke* 2016; 11: 544-548.
17. Kowoll A, Weber A, Mpotsaris A, et al. Direct aspiration first pass technique for the treatment of acute ischemic stroke: Initial experience at a European stroke center. *J Neurointerv Surg* 2016; 8: 230-234.



READY-MADE
CITATION

Meyer L, Politi M, Alexandrou M, Roth C, Brunner F, Kastrup A, Papanagiotou P. Primary Aspiration Technique in Endovascular Stroke Treatment. *Hell J Radiol* 2017; 2(2): 20-27.