

## CLINICAL CASE - TEST YOURSELF Urogenital Imaging

# A painful, enlarged left hemiscrotum

Ioanna Klapa, Ourania Preza, Aristeidis Antoniou

*Department of Radiology, School of Medicine, National and Kapodistrian University of Athens,  
Aretaieion Hospital, Athens, Greece*

SUBMISSION: 24/2/2017 | ACCEPTANCE: 18/8/2017

## PART A

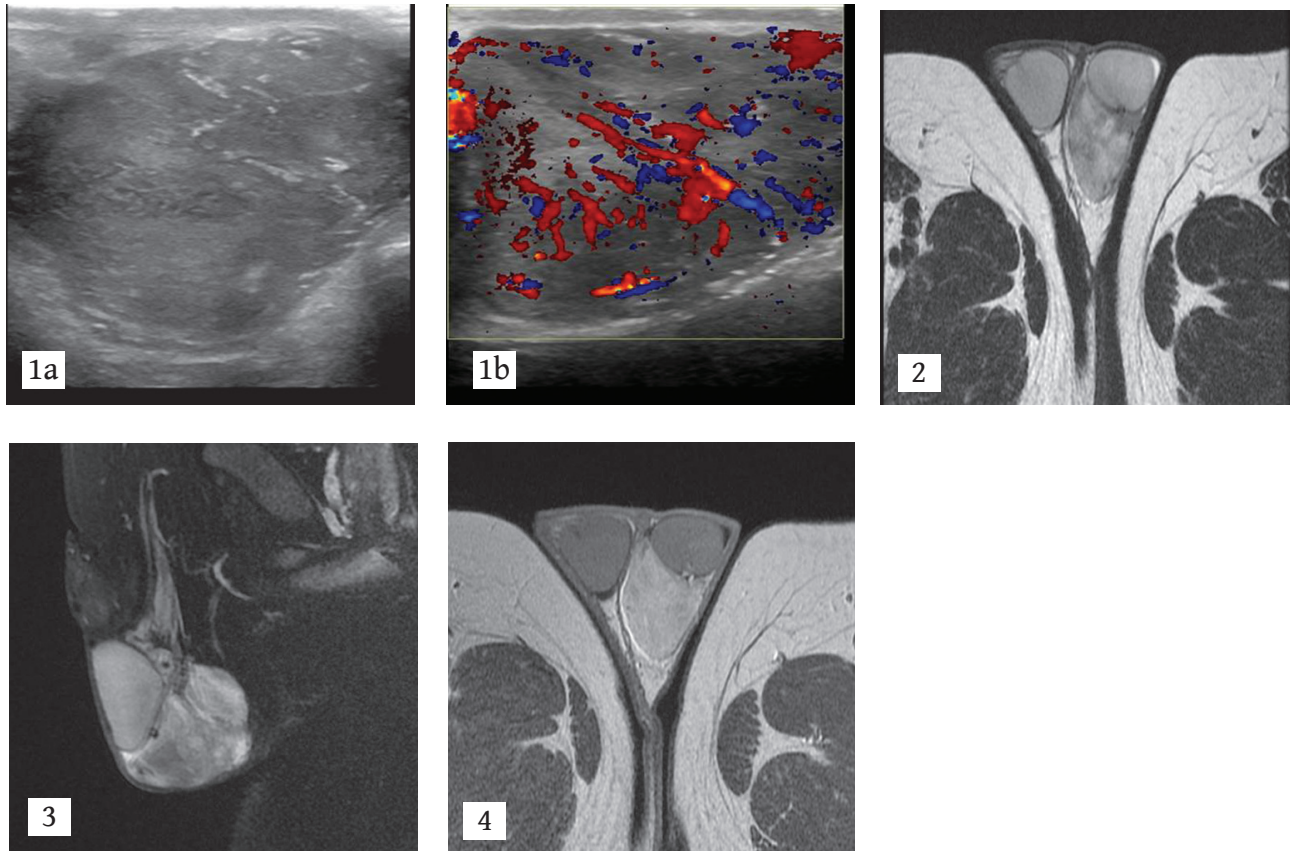
A 16-year-old male adolescent presented with a 1-month history of mildly painful swelling on the left hemiscrotum. The onset of the symptoms was insidious. The patient had no other clinical manifestations. Physical examination showed a palpable mass of approximately 8 cm in diameter on the left side of the scrotum. There were

no palpable inguinal lymph nodes. Medical history was unremarkable. Tumour serum markers and laboratory findings were normal. Ultrasound (US) was performed initially; the patient referred to magnetic resonance imaging (MRI) due to inconclusive US findings. US and MRI of the scrotum are shown below.



CORRESPONDING  
AUTHOR,  
GUARANTOR

Ioanna Klapa,  
Department of Radiology, School of Medicine, National and Kapodistrian  
University of Athens, Aretaieion Hospital, 76 Vasilissis Sofias, Athens 11528,  
Greece, E-mail: ioanna.klapa@yahoo.gr



**Fig. 1.** US: a) Gray scale US image of the left hemiscrotum, sagittal plane.

b) Colour Doppler image, sagittal plane of the same patient as in Fig. 1a

**Fig. 2.** MRI: Axial T2W image

**Fig. 3.** MRI: Sagittal fat-suppressed T2W image

**Fig. 4.** MRI: Axial contrast-enhanced T1W image

## PART B

**Diagnosis: Embryonal paratesticular rhabdomyosarcoma**

Solid paratesticular tumours, both malignant and benign, are a very uncommon entity. Paratesticular rhabdomyosarcoma (PRMS), although very rare (7% of all rhabdomyosarcomas) [1] is the most common malignancy of the paratestis in children and young adults. The spermatic cord, the epididymis and the tunica albuginea of the testis are the most common intrascrotal sites of origin of this mesenchymal tumour [2]. The age distribution has two peaks, at 1-5 and at 16 years [3]. The most common histologic type is embryonal (90%), followed by pleomorphic and alveolar, which has the worst prognosis [4]. Patients usually complain of a painless unilateral scrotal enlargement. Only 7% of patients present with pain, as in our case. Hydrocoele and scrotal oedema may be present as well [5]. No specific serum markers have been identified so far; alpha-fetoprotein (AFP), beta human chorionic gonadotropin (b-HCG) and carcinoembryonic antigen (CEA) are usually normal [6].

Scrotal US is the first imaging modality to be performed, because it is a non-invasive, widely available, costless and easily reproducible imaging method, which provides a quick overview of the scrotum excluding acute pathology (torsion, inflammation). PRMS sonographic findings include the presence of a well-defined, hypoechoic, heterogeneous and hypervascular mass, however, they are non-specific. Differential diagnosis should be made from benign paratesticular tumours (adenomatoid tumours, fibromas, leiomyomas, haemangiomas) which are more common, or inflammatory processes (e.g. acute epididymitis), all of which may share similar clinical and imaging characteristics (Table 1). Other benign scrotal pathologies include spermatic cord lipoma, which is the most common benign mass of the paratestis and epidermoid inclusion cyst; however both entities have typical imaging features and most of the times they can be easily differentiated from PRMS.

MRI is helpful in localising a scrotal mass, whether intratesticular or paratesticular, and should be used in cases of inconclusive US findings. It can show the mass to be separate from the displaced testis, by identifying the low T2W signal of the tunica albuginea encircling the organ. The tumour is homogeneous and indistinguishable from the nor-

Table 1.

**Benign paratesticular tumours**

Spermatic cord lipoma

Adenomatoid tumour

Epididymal leiomyoma

Epidermoid inclusion cyst

Spermatic cord fibroma

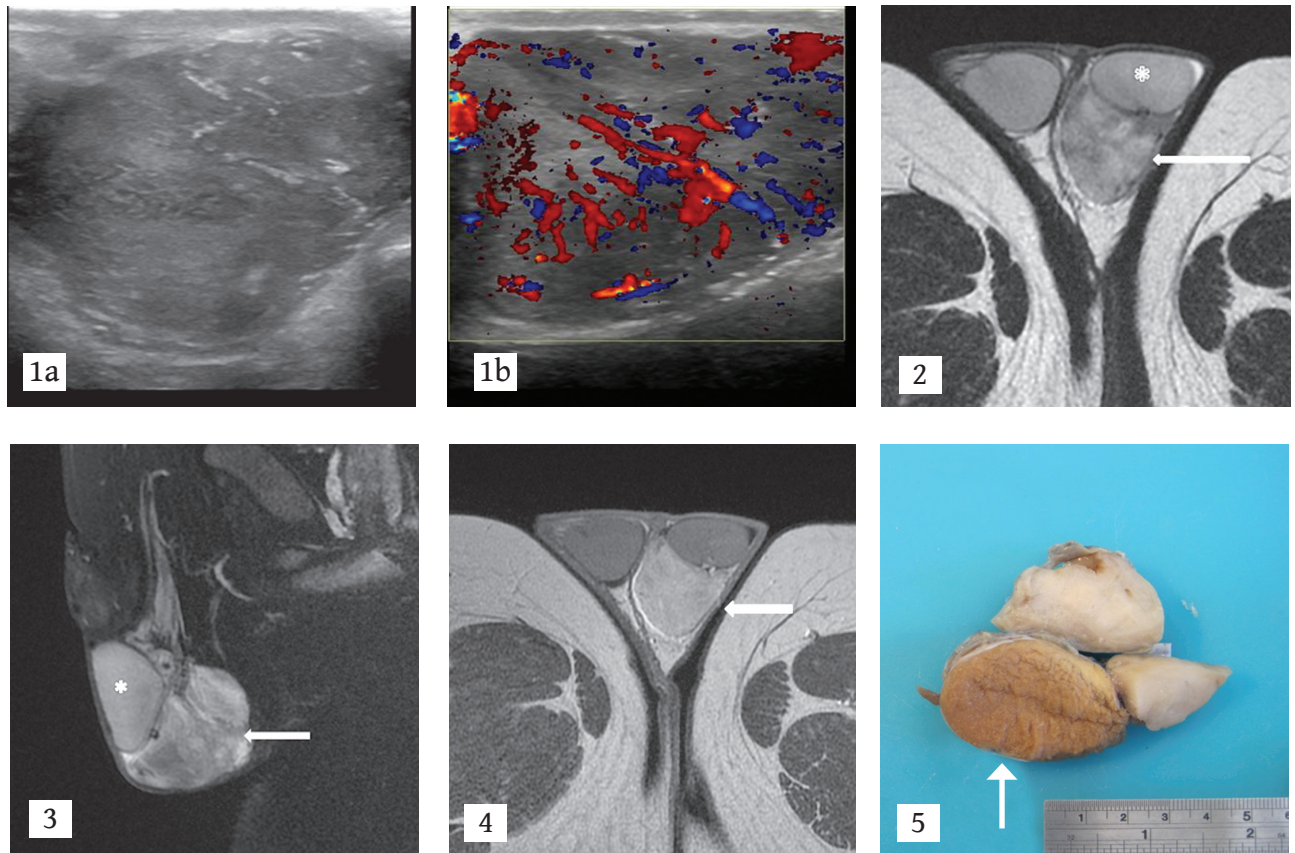
Scrotal haemangioma

mal testis on T1W images but shows a strong homogenous enhancement on contrast enhanced T1W images. On T2W images it is heterogeneous, with similar signal intensity to the normal testis. Furthermore addition of DWI can help differentiate between malignant and benign testicular pathology, as malignancy shows restricted diffusion [7]. MRI also provides information on local spread of the disease and involvement of adjacent lymph nodes [8].

The final diagnosis is made histologically. The tumour consists mostly of primitive round cells with small dark nuclei and rhabdomyoblasts [2]. PRMS is an aggressive neoplasm and some patients present with distant metastases. Computed tomography (CT) of the chest and abdomen should be performed for staging. The tumour spreads via the lymphatics to the paraaortic and iliac lymph nodes or via a haematogenous route to the lung, liver and cortical bones [6, 8]. Treatment in localised disease includes radical high inguinal, ipsilateral orchidectomy, and retroperitoneal lymph node dissection, as well as adjuvant chemotherapy, with actinomycin, vincristine and cyclophosphamide, combined with radiation therapy where necessary (if nodal metastases are present). In metastatic disease chemotherapy and radiotherapy are recommended by some protocols [9]. Prognosis depends on the histologic type and stage of the disease, with localised disease having a very good prognosis with a 5-year survival over 90%, whereas, in metastatic disease the rate drops to 22%. Patient age and tumour size are important prognostic factors with improved outcome for patients <10 years old and for tumor size <5 cm [1, 10]. **R**

**Conflict of interest:**

The authors declared no conflicts of interest.



**Fig. 1.** US: a) Gray scale US image of the left hemiscrotum, sagittal plane: There is a well-defined, hypoechoic, ovoid mass of solid nature, 5 cm in diameter. The normal testis and epididymis are indistinguishable. b) Colour Doppler image, sagittal plane of the same patient as in Fig. 1a: The mass shows increased intraparenchymal vascularity.

**Fig. 2.** MRI: Axial T2W image: There is a heterogeneous mass (arrow) within the left hemiscrotum with signal intensity close to the normal testicular parenchyma (asterisk). The mass is separated from the normal left testis by the low signal intensity of the tunica albuginea.

**Fig. 3.** MRI: Sagittal fat-suppressed T2W image: Left paratesticular mass (arrow) appears heterogeneous, mainly hyperintense, adjacent to the ipsilateral testis (asterisk).

**Fig. 4.** MRI: Axial contrast-enhanced T1W image: Left paratesticular mass enhances strongly (arrow). Note the normal testes.

**Fig. 5.** Surgicopathological specimen: Lobulated grey-white gross pathological specimen of the removed paratesticular rhabdomyosarcoma (arrow).



## KEY WORDS

rhabdomyosarcoma; scrotum; US; MRI

## REFERENCES

1. Ferrari A, Bisogno G, Casanova M, et al. Paratesticular rhabdomyosarcoma: Report from the Italian and German Cooperative Group. *J Clin Oncol* 2002; 20(2): 449-455.
2. Reeves HM, MacLennan GT. Paratesticular rhabdomyosarcoma. *J Urol* 2009; 182(4): 1578-1579.
3. Dangle PP, Correa A, Tennyson L, et al. Current management of paratesticular rhabdomyosarcoma. *Urol Oncol* 2016; 34(2): 84-92.
4. Kumar R, Kapoor R, Khosla D, et al. Paratesticular rhabdomyosarcoma in young adults: A tertiary care institute experience. *Indian J Urol* 2013; 29(2): 110-113.
5. Wang HL, Liu LY, Tian RH, et al. Embryonal rhabdomyosarcoma of the epididymis presenting as epididymitis: A case report. *Mol Clin Oncol* 2016; 4(4): 625-627.
6. Bouchikhi AA, Mellas S, Tazi MF, et al. Embryonic paratesticular rhabdomyosarcoma: A case report. *J Med Case Rep* 2013; 7:93. doi: 10.1186/1752-1947-7-93.
7. Nicola R, Menias CO, Dahiya N, et al. Review of paratesticular pathology: Findings on ultrasound and MRI. *Abdom Radiol (NY)* 2017; 42(2): 585-601.
8. Mason BJ, Kier R. Sonographic and MR imaging appearances of paratesticular rhabdomyosarcoma. *AJR Am J Roentgenol* 1998; 171(2): 523-524.
9. Boudahna L, Benbrahim Z, Amaadour L, et al. Paratesticular rhabdomyosarcoma in adults: Three case reports and review of literature. *Pan Afr Med J* 2014; 19: 279. doi: 10.11604/pamj.2014
10. Seitz G, Fuchs J, Martus P, et al. Outcome, treatment, and treatment failures in patients suffering localized embryonal paratesticular rhabdomyosarcoma: Results from the "Cooperative Weichteilsarkom Studiengruppe" trials CWS-86, -91, -96, and-2002P. *Ann Surg* 2016; 264(6): 1148-1155.



## READY-MADE CITATION

Klapa I, Preza O, Antoniou A. A painful, enlarged left hemiscrotum. *Hell J Radiol* 2017; 2(4): 74-78.