

Abrupt onset of pain and progressive weakness in a young female

Ekaterini Tavernaraki¹, Chrissafoula Kolofousi², John Kalogeropoulos³

¹Department of CT-MR, Evangelismos Hospital, Athens, Greece

²Iatropolis, Athens, Greece

³Department of Radiology, Evangelismos Hospital, Athens, Greece

SUBMISSION: 7/4/2017 | ACCEPTANCE: 23/5/2017

PART A

A 38-year-old female presented with abrupt onset of dull aching pain of pelvis, movement limitation and progressive weakness. Laboratory studies including complete blood count, complete metabolic panel, alkaline phos-

phatase, C-reactive protein, erythrocyte sedimentation rate were all within normal limits.

She underwent plain radiograph, CT and MRI of the pelvis (**Fig. 1-5**). Biopsy followed.



CORRESPONDING
AUTHOR,
GUARANTOR

Ekaterini Tavernaraki, Evangelismos Hospital, 45-47 Ypsilantou Str.
Athens 10676, Greece
E-mail: katiatav@yahoo.com

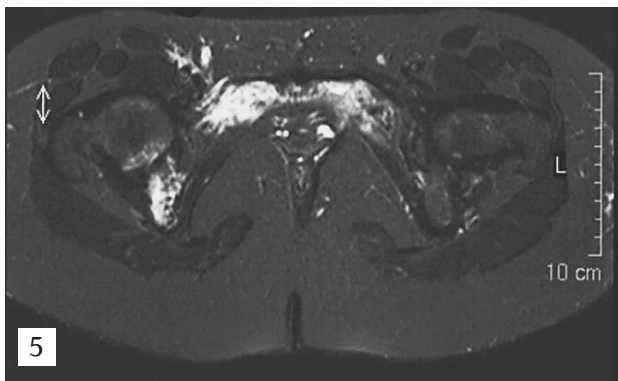
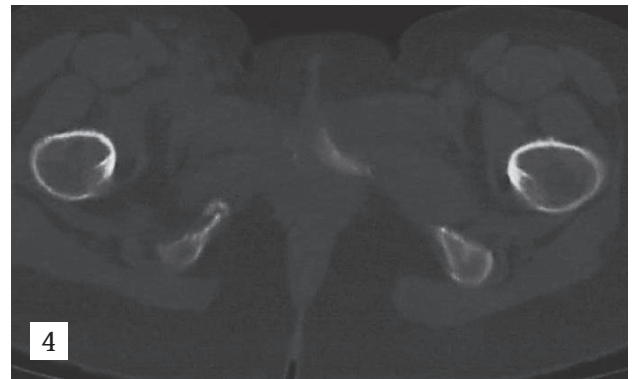
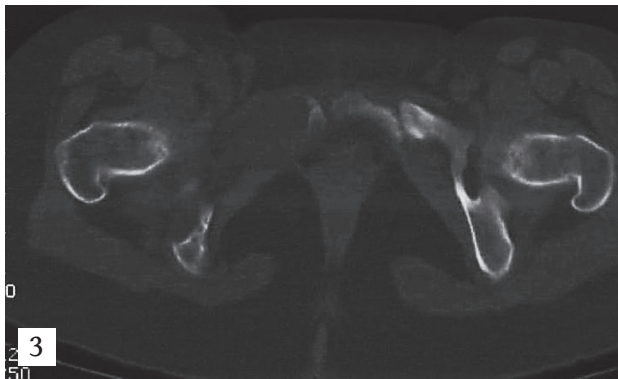
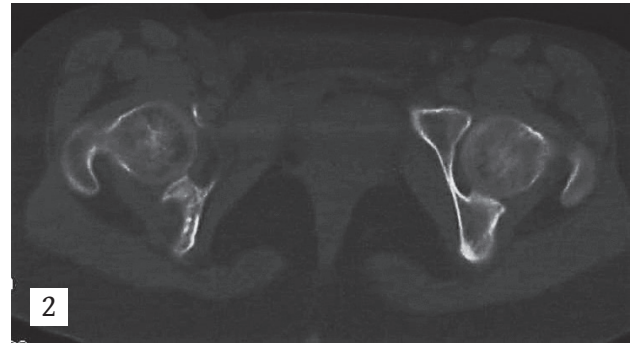
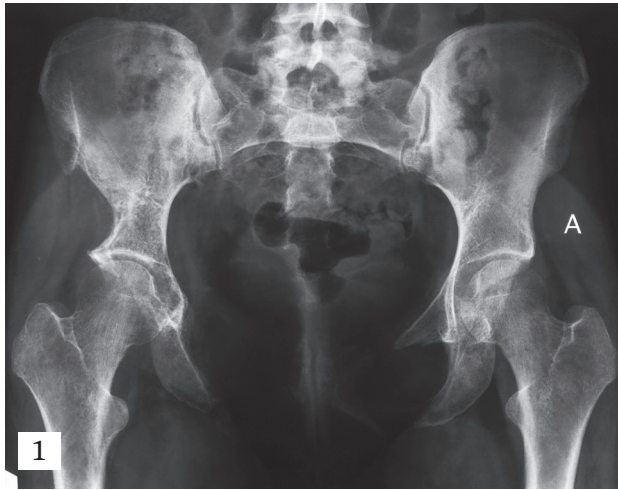

Fig. 1: Plain AP radiograph of the pelvis

Fig.2-4: Axial CT images of the pelvis using bone window

Fig.5: Axial STIR MR image of the pelvis

PART B

Diagnosis: Gorham-Stout Syndrome of Pelvis

Gorham-Stout syndrome is an extremely rare disease of the bones, with a slight preference to the male gender. Jackson first described idiopathic osteolysis in 1838. In 1955, Gorham and Stout recognised it as a syndrome. Nowadays, it is known under various eponyms, such as haemangiomas, disappearing bone disease, vanishing bone disease, massive osteolysis, Gorham's syndrome, Gorham-Stout syndrome and Gorham's disease. Although the majority of Gorham-Stout syndrome occurs during childhood, more than 1/3 of the affected patients are older than 35 years. About 50% have an associated history of trauma [1-3]. Contiguous bony involvement is usual without skip areas, multiple foci, or metastases. The shoulder and the pelvis are the most common sites of involvement. Other locations such as the humerus, scapula, clavicle, ribs, sternum, mandible, spine and hand can be affected.

It is a sporadic benign osteolytic disease of unknown aetiology. The exact nature of the procedure that leads to the osteolysis has not yet been clarified. There are many theories regarding this concern such as abnormal vascularisation, haemangiomas or lymphangiomas hyperplasia, due to fracture, osteoclastic activation etc. [4].

Clinical presentations depend on the affected area. The first manifestations of the disease can be pain, pathologic fractures or weakness of the suffering location. The pain can be insidious or sudden. The lesion can also be accompanied by soft tissue mass and swelling. The disease is usually progressive, but eventually stabilisation of the affected bone is the most common sequel.

Spontaneous regression has been reported only in few cases. In some patients part of the absorbed bone may be restored automatically [5], whereas in others the affected area may recover clinically and radiologically after radiotherapy [6].

Although bone deformation can be devastating, serious complications are rare. Chylothorax may occur from the direct extension of lymphangiectasia into the pleural cavity, or via invasion of the thoracic duct from diseases of the ribs, scapula, or thoracic vertebrae [7]. This can lead to a high rate of morbidity and mortality without surgical intervention.

Death can occur due to involvement of the thoracic cage, the lung or the pleura, that can lead to respiratory deficiency. Bone infection and septic shock is a rare cause of death. Paraplegia appears when the osteolysis of the spine causes invasion of the spinal cord. Pleural effusion may occur. Kasabach-Merritt syndrome can be another complication.

Radiographically, the earliest changes are foci of intramedullary and subcortical lucency resembling patchy osteoporosis [3]. Subsequently, slowly progressive atrophy, dissolution, fracture, fragmentation and disappearance of portion of the bone occurs with tapering or "pointing" of the remaining osseous tissue and atrophy of soft tissues. A typical finding is lack of sclerosis or osteoblastic reaction [8]. The process can extend across joints and results into varying degrees of deformity. Soft tissue invasion near the affected bones has been a feature of several reported cases.

CT is useful in the delineation of soft tissue extension and helps biopsy guidance. 3-D CT reconstructions have been helpful in surgical planning [9].

Lymphangiography has been used to assess the thoracic duct in patients with chylothorax. The lymphatic vessels and nodes have normal appearance, although altered flow can lead to obstruction and oedema [10]. Angiography depicts absence of neovascularity. Bone scan can show in early stages increased vascularity and later on an area of no or little radioisotope uptake [10].

MR images show morphologic disappearance of bone and bone marrow changes of increased or decreased signal intensity due to haemorrhage at different stages [10].

The pathological process is the replacement of normal bone by aggressively expanding vascular tissue similar to haemangioma or lymphangioma. This causes massive bone loss. Histologically, involved bones show a non-malignant proliferation of thin-walled vessels, which may be capillary, sinusoidal or cavernous. In late stages, there is progressive dissolution of the bone leading to massive osteolysis with replacement of osseous tissue by fibrous tissue.

Detailed history, physical examination and appropriate blood tests should be undertaken in order to exclude other common underlying causes of osteolysis such as infection, primary or metastatic cancer, inflammatory and endocrine disorders. The diagnosis of

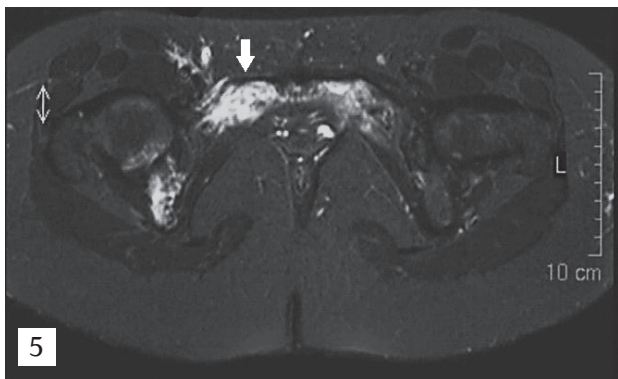
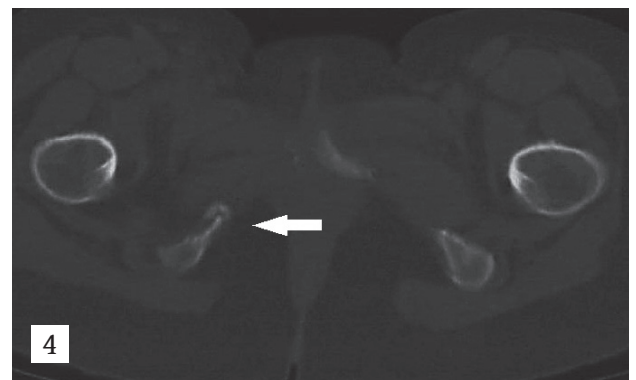
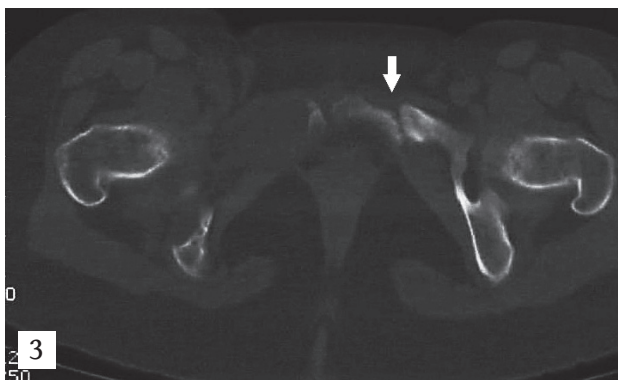
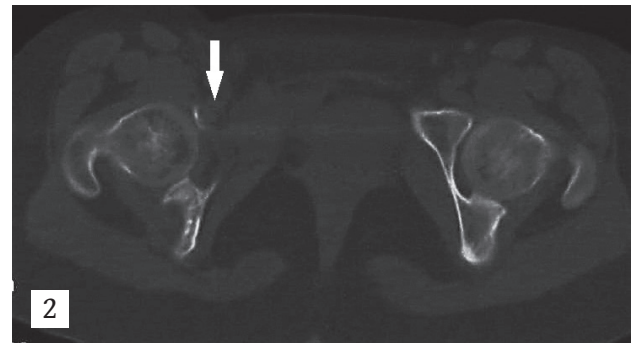
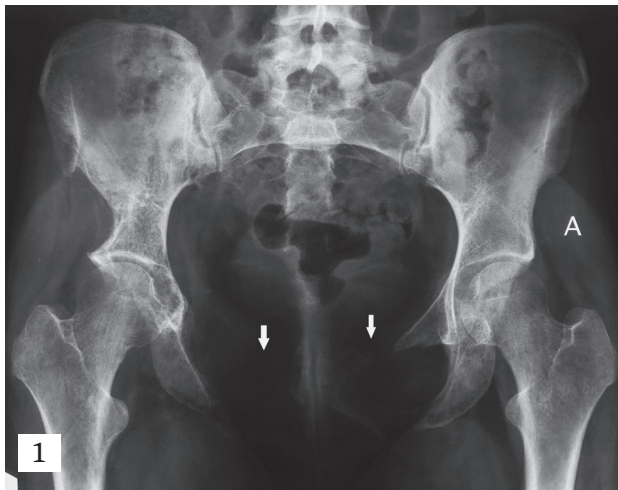


Fig. 1: Radiography reveals osteolysis of superior and inferior rami of both pubic bones (arrows) and right inferior ischial ramus. There is disruption of iliopectineal line at right side. Bone ends at the region of osteolysis are “pointing”

Fig.2: CT reveals osteolysis of anterior column of right acetabulum (arrow). There is no soft tissue mass at the region of osteolysis

Fig.3: CT reveals osteolysis of body and inferior ramus of right pubic bone and inferior ramus of right ischium. There is no soft tissue mass at the region of osteolysis. Also, there is a fracture of left pubic bone with sclerotic margins (arrow) suggesting pseudarthrosis

Fig.4: CT showing a fracture of inferior ramus of right ischium with pseudarthrosis (arrow)

Fig.5: Axial STIR MR image shows high signal intensity within the bone marrow (arrow)

Gorham-Stout syndrome should be set after excluding these conditions.

The differential diagnosis of Gorham-Stout syndrome also includes angiosarcoma, essential osteolysis and hereditary osteolysis such as acroosteolysis of Hadjue and Cheney, idiopathic multicentric osteolysis etc. Skeletal angiomas can cause osteolysis but tend to preserve bone cortex and do not spread into adjacent soft tissue [8]. Essential osteolysis is characterised by resorption of carpal bones, tarsal bones or both with progressive renal failure. Hereditary osteolysis occurs in childhood, lacks vascular proliferation, involves primarily hands and feet and tends to be multicentric [3]. Osteolysis may also result from systemic diseases, such as rheumatoid arthritis, syphilis and hyperparathyroidism [3]. Finally, myeloma and lymphoma should be considered in the differential diagnosis as they can cause moth-eaten appearance [4].

Our patient had no history of systemic disease or infection and all laboratory findings were within normal

limits. Radiography revealed massive osteolysis of superior and inferior ramus of both pubic bones and extension to the right inferior ischial ramus. Both bone ends at osteolytic areas were sharply pointed (**Fig. 1**). CT findings included massive osteolysis of both pubic bones, extension to the right acetabulum and pathologic fractures of left pubic bone and right inferior ischial ramus. There was no associated soft tissue mass in the affected areas (**Fig. 2-4**). MRI revealed high signal intensity in the abnormal bone marrow on STIR sequence (**Fig. 5**). Pathologic findings were typical for Gorham-Stout syndrome.

In conclusion, Gorham-Stout syndrome is a progressive idiopathic osteolysis of one bone/contiguous bones, usually unicentric with development of haemangiomatous tissue in the lytic region. **R**

Conflict of interest:

The authors declared no conflicts of interest.



KEY WORDS

idiopathic osteolysis; CT; MR; vanishing bone

REFERENCES

1. Gorham LW, Wright AW, Shultz HH, et al. Disappearing bones: A rare form of massive osteolysis: Report of two cases, one with autopsy findings. *Am J Med* 1954; 17: 674-682.
2. Gorham LW, Stout AP. Massive osteolysis (acute spontaneous absorption of bone, phantom bone, disappearing bone): Its relation to hemangiomas. *J Bone Joint Surg [Am]* 1955; 37-A: 985-1004.
3. Choma ND, Biscotti CV, Bauer TW, et al. Gorham's syndrome: A case report and review of the literature. *Am J Med* 1987; 83: 1151-1156.
4. Moller G, Priemel M, Amling M, et al. The Gorham-Stout syndrome (Gorham's massive osteolysis): A report of six cases with histopathological findings. *J Bone Joint Surg [Br]* 1999; 81-B: 501-506.
5. Campbell J, Almond HG, Johnson R. Massive osteolysis of the humerus with spontaneous recovery. *J Bone Joint Surg [Br]* 1975; 57-B: 238-240.
6. Hanly JG, Walsh NM, Bresnihan B. Massive osteolysis in the hand and response to radiotherapy. *J Rheumatol* 1985; 12: 580-582.
7. Chavanis N, Chaffanjon P, Frey G, et al. Chylothorax complicating Gorham's disease. *Ann Thorac Surg* 2001; 72: 937-939.
8. Collins J. Case 92: Gorham syndrome. *Radiology* 2006; 238: 1066-1069.
9. Vinee P, Tanyu O, Hauenstein KH, et al. CT and MRI of Gorham Syndrome. *J Comput Assist Tomogr* 1994; 18: 985-989.
10. Dominguez R, Washowich TL. Gorham's disease or vanishing bone disease: Plain film CT, and MRI findings of two cases. *Pediatr Radiol* 1994; 24: 316-318.



READY - MADE
CITATION

Tavernaraki E, Kolofousi C, Kalogeropoulos J. Abrupt onset of pain and progressive weakness in a young female. *Hell J Radiol* 2017; 2(4): 68-73.