

# Variations of ADC of normal uterine zones in postmenopausal and reproductive women

Athina C. Tsili<sup>1</sup>, Alexandra Ntorkou<sup>1</sup>, Thomas Vrekoussis<sup>2</sup>, Vasilios Maliakas<sup>1</sup>,  
Maria I. Argyropoulou<sup>1</sup>

<sup>1</sup>Department of Clinical Radiology, Medical School, University of Ioannina, 45110, Ioannina, Greece

<sup>2</sup>Department of Obstetrics and Gynaecology, Medical School, University of Ioannina, 45110, Ioannina, Greece

SUBMISSION: 13/07/2016 | ACCEPTANCE: 10/10/2016

## ABSTRACT

**Purpose:** The aim was to establish normal values and to compare the apparent diffusion coefficient (ADC) of the uterine zones in postmenopausal and reproductive age women in the three phases of the menstrual cycle.

**Materials and Methods:** This retrospective study included 194 women. All magnetic resonance imaging (MRI) examinations were performed on a 1.5 T scanner. Diffusion-weighted imaging (DWI) was performed using a single shot, multislice spin-echo diffusion planar sequence and b-values of 0 and 800 s/mm<sup>2</sup>. ADC of normal endometrium/myometrium was classified into four groups according to menstrual status: Menopause, menstrual, proliferative and secretory phase. Analysis of Variance followed by the Least Significant Difference (LSD) test was used for statistical analysis.

**Results:** The mean and SD (standard deviation) of ADC ( $\times 10^{-3}$  mm<sup>2</sup>/s) of the endometrium was: meno-

pause:  $1.36 \pm 0.18$ ; menstrual phase:  $1.24 \pm 0.22$ ; proliferative phase:  $1.38 \pm 0.20$ ; and secretory phase:  $1.50 \pm 0.18$  (F: 12.317, P < 0.001). The LSD test showed differences between menopause and menstrual phase (P: 0.020) and between menopause and secretory phase (P: 0.001), but not between menopause and proliferative phase (P: 0.643). The mean and SD (standard deviation) of ADC ( $\times 10^{-3}$  mm<sup>2</sup>/s) of the myometrium was: menopause:  $1.60 \pm 0.15$ ; menstrual phase:  $1.92 \pm 0.28$ ; proliferative phase:  $1.72 \pm 0.24$ ; and secretory phase:  $1.86 \pm 0.27$  (F: 16.034, P < 0.001). Significant difference was observed between all phases (P < 0.05).

**Conclusion:** A wide variation of ADC of normal endometrium/myometrium was found between postmenopausal and reproductive age women. A standard reference of ADC of normal uterine zones is helpful, serving as a baseline when interpreting uterine diseases.



CORRESPONDING  
AUTHOR,  
GUARANTOR

Athina C. Tsili, Department of Clinical Radiology, Medical School,  
University of Ioannina, University Campus, 45110, Ioannina, Greece,  
E- mails: a\_tsili@yahoo.gr, atsili@cc.uoi.gr



## KEY WORDS

apparent diffusion coefficient; diffusion weighted MRI; pre menopause; post menopause; uterine zones

## 1. Introduction

Diffusion-weighted imaging (DWI) is a functional imaging technique that provides information about water mobility, tissue cellularity and the integrity of the cellular membranes [1]. It is now considered part of the standard MRI protocols for the evaluation of the female pelvis [2-16]. Clinical applications of DWI related to endometrial carcinoma have been mainly focused on detection, differentiation from benign endometrial lesions and preoperative staging of the disease [2-13]. DW sequences are particularly helpful in assessing the depth of myometrial invasion by endometrial cancer in challenging conditions, such as coexistence of leiomyomas and/or adenomyosis, thinning of the myometrium, poor tumor-to-myometrium contrast, loss of the junctional zone definition, and extension of the neoplasm into the cornua [2-12]. DWI is also beneficial in staging of advanced carcinoma of the endometrium, in depicting extrauterine pelvic disease, in assessing tumor response to chemotherapy and in the detection of tumor recurrence [2-12]. Compared with benign uterine lesions, and also with normal endometrium/myometrium, the mean ADC of endometrial cancer has been shown to be lower [2-13]. However, no definite cut-off predictive of the presence of carcinoma of the endometrium has yet been established.

It is known that normal uterus undergoes distinctive morphologic and functional changes during the different phases of the menstrual cycle and aging [17-20]. The width and MR signal intensity of the normal endometrium/myometrium changes during the menstrual cycle [17-20]. In postmenopausal women, the uterine corpus shrinks and zonal anatomy becomes indistinct [17]. There are few studies reporting significant intraindividual and interindividual variations of normal uterine ADC values in reproductive women during the menstrual cycle [21-24]. As to the author's knowledge, there are no reports in the English-language literature comparing the ADC of normal uterus between postmenopausal and premenopausal women.

The aim of this retrospective study was to establish normal values and to compare the ADC of the uterine zones in postmenopausal and reproductive age women in the three phases of the menstrual cycle.

## 2. Materials and Methods

### 2.1 Study group

This was a retrospective study conducted at a single institution. The study cohort included 194 women (age range: 21-86 years, mean age: 45.4 years) referred to the Gynaecology clinic with various clinical indications, 101 of which were included in a previous report [22]. One hundred and thirty eight women were premenopausal (age range: 21-56 years, mean age: 39.9 years), each with regular menstrual cycle, of approximately  $28 \pm 3$  days and 56 were postmenopausal (age range: 48-86 years, mean age: 66.5 years). Postmenopausal status was defined as date of last menstrual period more than one year before the present study. Among reproductive age group, 31 women were in the menstrual phase, 46 were in the proliferative phase and 61 in the secretory phase. The menstrual phase included the first four days of menstruation. The proliferative phase started on the fifth day until ovulation and the secretory phase lasted for the remaining two weeks. Patients with histologically confirmed endometrial carcinoma of FIGO stage  $\geq$ IB, cases undergone pelvic irradiation and women with recent use of oral contraceptives or hormonal replacement therapy were excluded from the analysis.

MRI and/or histopathologic findings included the following: normal findings ( $n=72$ , including 26 women with cervical intraepithelial neoplasia examined before [ $n=21$ ] and/or after [ $n=5$ ] large loop excision of the transformation zone), uterus leiomyomas ( $n=36$ , in one case with coexisting adenomyosis), benign ovarian cystic lesions ( $n=26$ ), endometriosis ( $n=12$ ), benign ovarian tumors (mature cystic teratoma:  $n=5$ , cystadenofibroma:  $n=1$ , stromal ovarian tumors:  $n=2$ ), ovarian torsion ( $n=1$ ), pelvic inflammatory disease ( $n=4$ ), endometrial polyp ( $n=8$ ), cervical polyp ( $n=1$ ), adenomatous endometrial hyperplasia ( $n=1$ ), endometrial cavity fluid ( $n=3$ ), endometrial carcinoma ( $n=7$ , with tumor limited to the endometrium or invading less than 50% of the myometrium), other female pelvic malignancies (cervical carcinoma:  $n=6$ , ovarian carcinoma:  $n=3$ , tubal carcinoma:  $n=1$ , and vulvar carcinoma:  $n=4$ ), and rectal cancer ( $n=1$ ). Histopathologic confirmation of normal endometrium/myometrium was obtained in 67 cases.

**Table 1.** MR protocol

Sequences	spin-echo T1	turbo spin-echo T2	DW
Plane	transverse	transverse, sagittal	transverse
TR (msec)	500	4,000	4,132
TE (msec)	16	120	116
Slice thickness	3-5 mm	3-5 mm	3-5 mm
Gap	0.3-0.5 mm	0.3-0.5 mm	0.3-0.5 mm
FOV (cm)	28	28	28
Matrix (mm)	256×256	256×256	256×256
<i>b</i> values s/mm <sup>2</sup>			0, 800

In the remaining 127 cases, uterine zones were characterized as 'normal' based on MRI appearance and the absence of uterine disease during subsequent clinical and/or imaging follow-up studies.

The study protocol was approved by the institutional ethics committee and written informed consent was obtained from all participants, prior to the MRI examinations.

Twenty seven ADC calculations of the endometrium were not included in the analysis, due to the following: Endometrial carcinoma ( $n=7$ ), endometrial polyp ( $n=8$ ), adenomatous endometrial hyperplasia ( $n=1$ ), endometrial cavity fluid ( $n=3$ ), multiple leiomyomas distorting the endometrial cavity ( $n=1$ ), and thin normal endometrium, difficult to measure ( $n=7$ ). Excluded were also four ADC calculations of the myometrium, due to the presence of multiple leiomyomas.

## 2.2 MRI protocol

All MRI examinations were performed on a 1.5 T Intera scanner (Philips Medical Systems, Cleveland, OH, USA), using a pelvic phased-array coil. Transverse spin-echo T1-weighted images, transverse and sagittal turbo spin-echo T2-weighted images were used for data interpretation. DWI was performed along the axial plane, during quiet breathing using a single shot, multi-slice spin-echo planar diffusion pulse sequence with *b*-values of 0 and 800 s/mm<sup>2</sup>. The total acquisition time was 29 sec. The orientation and location of DWI slices were identical to the conventional transverse slices. The MR protocol used for data interpretation in this study is presented in **Table 1**.

## 2.3 MRI data interpretation

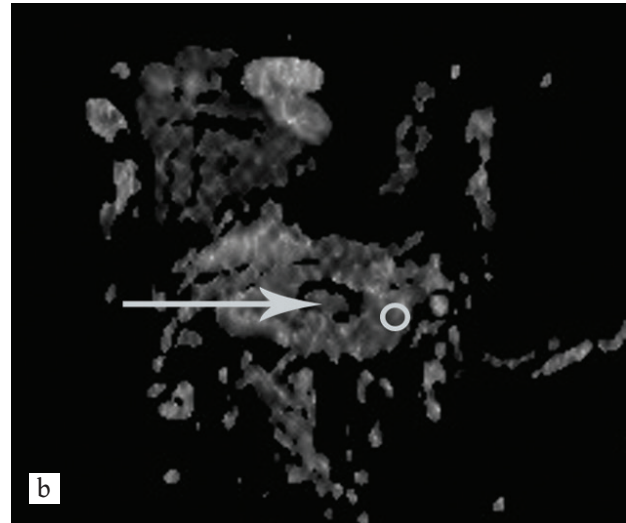
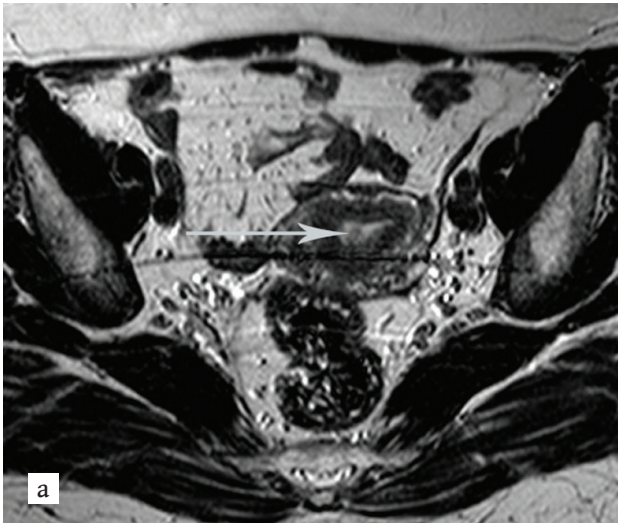
MRI data were interpreted by two radiologists (reader 1: Three years of experience, and reader 2: Twelve years of experience) and any discrepancy was resolved by consensus. DW images were read in conjunction with the transverse T2-weighted images. The ADC maps were created on a workstation (Philips Medical Systems, Cleveland, OH, USA). Signal intensity mean ADC values of circular regions of interest (ROIs) were calculated on the ADC maps that contained the largest cross-section of the normal endometrium/myometrium, so that the largest ROI could be drawn. Three measurements were made and averaged.

## 2.4 Statistical analysis

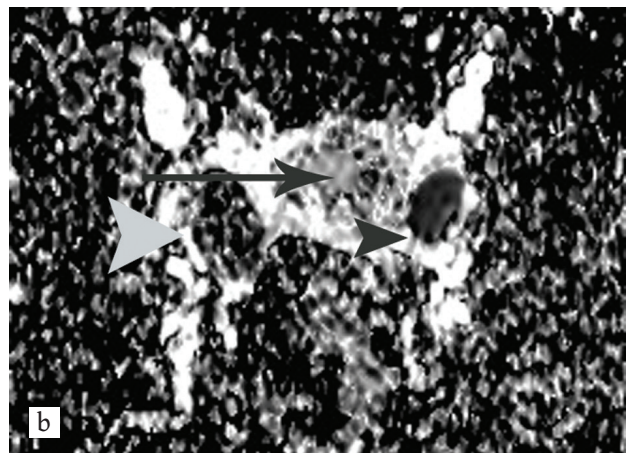
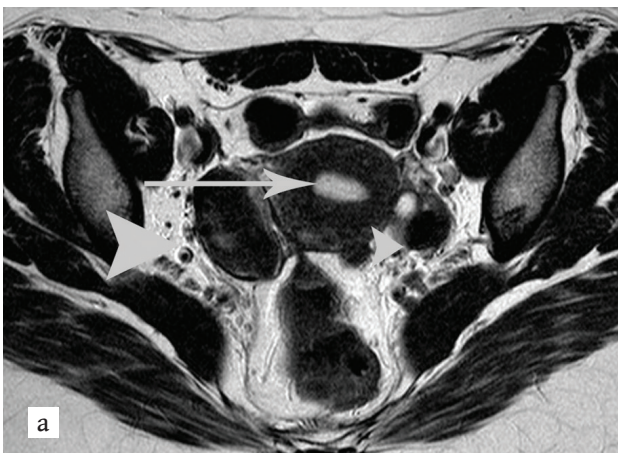
The ADC of normal endometrium/myometrium was classified into four groups according to menstrual status: menopause, menstrual, proliferative and secretory phase. The Kolmogorov-Smirnov test was used to assess normality of the parameters. The ADC of normal endometrium and myometrium for each phase separately was compared using one-way analysis of variance (ANOVA) followed by the Least Significance Difference (LSD) test. Statistical analysis was performed using IBM SPSS version 20.0. Statistical significance was set at *P*-value's of <0.05.

## 3. Results

The ADC of normal endometrium was measured in 167 cases, including 32 in the menopause, 31 in the menstrual phase, 44 in the proliferative phase and 60 cases in the secretory phase. The mean  $\pm$  s.d. of ADC values ( $\times 10^{-3}$  mm<sup>2</sup>/s) of normal endometrium were the follow-



**Fig. 1.** Transverse (a) turbo spin-echo T2-weighted image and (b) the corresponding ADC map in a 62-year old woman. MRI findings were unremarkable. The ADC of endometrium (long arrow) and myometrium (circle) was  $1.63 \times 10^{-3} \text{ mm}^2/\text{s}$  and  $1.82 \times 10^{-3} \text{ mm}^2/\text{s}$ , respectively



**Fig. 2.** Transverse (a) turbo spin-echo T2-weighted image and (b) the corresponding ADC map in a 33-year old woman with a history of endometriosis, examined during the secretory phase. The ADC of normal endometrium (long arrow) and myometrium was  $1.63 \times 10^{-3} \text{ mm}^2/\text{s}$  and  $1.9 \times 10^{-3} \text{ mm}^2/\text{s}$ , respectively. Bilateral endometriomas (arrowheads) appear with very low signal intensity on both T2-weighted images and ADC maps

ing: menopause:  $1.36 \pm 0.018$  (Fig. 1), menstrual phase:  $1.24 \pm 0.22$ , proliferative phase:  $1.38 \pm 0.20$ , and secretory phase:  $1.50 \pm 0.18$  (Fig. 2). The data followed a normal distribution as evaluated using the Kolmogorov-Smirnov test. The magnitude of variations of ADC values of normal endometrium during the different phases is presented in Table 2. ANOVA revealed differences of mean ADC between groups ( $F=12.31$ ,  $P<0.001$ ). The LSD test showed significant difference of the ADC of normal endometrium between menopause and menstrual phase ( $P: 0.020$ ) and between menopause and secretory phase ( $P: 0.001$ ). No difference was found between the ADC of endometri-

um during the menopause and the proliferative phase ( $P: 0.643$ ). Significant difference of the ADC of normal endometrium was found in the reproductive age groups, between menstrual and proliferative phase ( $P: 0.003$ ), between menstrual and secretory phase ( $P<0.001$ ), and between proliferative and secretory phase ( $P: 0.003$ ).

The ADC of normal myometrium was measured in 190 cases, including 54 women in the menopause, 30 women during menstruation, 45 in the proliferative phase and 61 in the secretory phase. The mean  $\pm$  s.d. of ADC ( $\times 10^{-3} \text{ mm}^2/\text{s}$ ) of normal myometrium was: menopause:  $1.60 \pm 0.015$  (Fig. 1), menstrual phase:  $1.92 \pm 0.28$ , proliferative

**Table 2.** ANOVA analysis between the ADC of the normal endometrium during the menopause, menstrual, proliferative and secretory phase

	Menopause (n=32)	Menstrual phase (n=31)	Proliferative phase (n=44)	Secretory phase (n=60)	F	P
mean $\pm$ SD ( $\times 10^{-3}$ mm <sup>2</sup> /s)	1.36 $\pm$ 0.18	1.24 $\pm$ 0.22	1.38 $\pm$ 0.20	1.50 $\pm$ 0.18		
maximum ( $\times 10^{-3}$ mm <sup>2</sup> /s)	1.80	1.79	1.96	1.86	12.31	0.000
minimum ( $\times 10^{-3}$ mm <sup>2</sup> /s)	1.07	0.88	1.10	0.96		

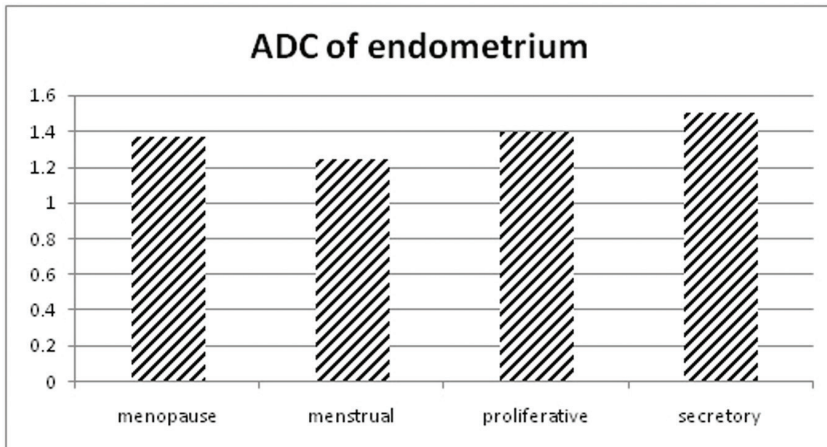
**Table 3.** ANOVA analysis of the ADC of the normal myometrium during the menopause, menstrual, proliferative and secretory phase

	Menopause (n=54)	Menstrual phase (n=30)	Proliferative phase (n=45)	Secretory phase (n=61)	F	P
mean $\pm$ SD ( $\times 10^{-3}$ mm <sup>2</sup> /sec)	1.60 $\pm$ 0.15	1.92 $\pm$ 0.28	1.72 $\pm$ 0.24	1.86 $\pm$ 0.27		
maximum ( $\times 10^{-3}$ mm <sup>2</sup> /sec)	1.92	3.00	2.39	2.49	16.03	0.000
minimum ( $\times 10^{-3}$ mm <sup>2</sup> /sec)	1.20	1.47	1.18	1.31		

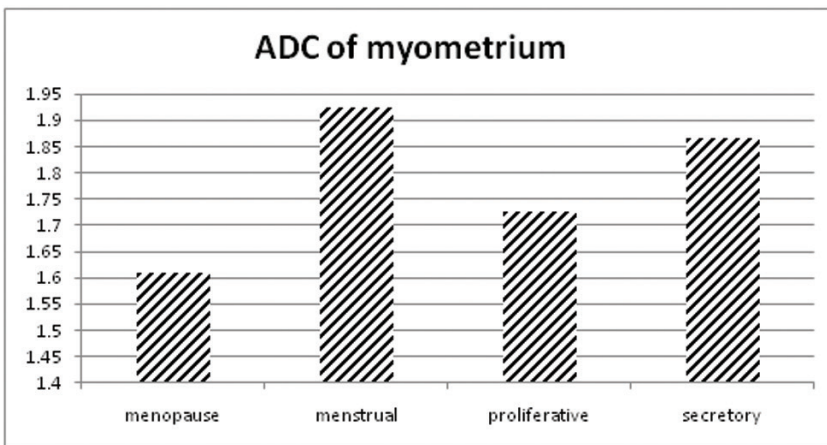
phase: 1.72  $\pm$  0.24, and secretory phase: 1.86  $\pm$  0.27 (Fig. 2). **Table 3** shows number of cases, mean ADC, standard deviations, minimum and maximum ADC for myometrium in postmenopausal and reproductive women. ANOVA revealed differences of mean ADC between groups (F=16.03, P<0.001). The LSD test showed a significant difference of the ADC of normal myometrium between menopause and different phases of the menstrual cycle (menopause and menstrual phase, P<0.001; menopause and proliferative phase, P: 0.015; menopause and secretory phase, P<0.001). Significant difference of the ADC of normal myometrium was found between menstrual and proliferative phase (P: 0.001), and between proliferative and secretory phase (P: 0.004). No difference was found between the menstrual and the secretory phase (P: 0.257). The inter-group variations of ADC of normal endometrium/myometrium are shown on **Figures 3** and **4** with the help of bar diagrams.

#### 4. Discussion

DWI is emerging as a promising complementary tool in a broad range of clinical applications in the female pelvis, including uterine diseases [1-16]. Due to its relatively short acquisition time, DWI can easily be added to routine MR protocols and is particularly useful in patients with contraindications to intravenous gadolinium-based contrast agents [1-16]. DW sequences are able to measure the random motion of water in tissues, thus helping to detect, characterize, stage and predict aggressiveness of endometrial carcinoma [3-12]. DWI has also been proved useful in the characterization of myometrial tumors [14-16]. Thomassin-Naggara et al. in a retrospective study of 51 myometrial tumors reported a diagnostic accuracy of 92.4% in differentiating benign from uncertain or malignant myometrial neoplasms by combining conventional and high b value DWI [16]. However, to help in the accurate diagnosis of uterine diseases, standard references of



*Fig. 3. Bar Diagram showing inter-group variations of ADC of normal endometrium*



*Fig. 4. Bar Diagram showing inter-group variations of ADC of normal myometrium*

the normal ADC of the uterine zones should exist.

T2-weighted images of the normal uterus in reproductive age women show variations in endometrial and myometrial width and signal intensity [17-20]. The endometrium is thin just after menstruation and progressively thickens during the proliferative and the secretory phase. The myometrium is also thin and relatively hypointense during menstrual and early proliferative phase, when compared to the higher signal intensity during the late proliferative and secretory phase [17-20]. A wide variation of ADC for the normal endometrium/myometrium during the different phases of the menstrual cycle was found in the present study and this was in accordance with our previous report [22]. Histopathologic changes of the normal uterus in premenopausal women explain the variations of the ADC of the endometrium/myometrium during the menstrual cycle [25-27]. The ADC of the normal endometrium was lower during the menstrual phase when compared with the proliferative and the secretory phase, and during the proliferative phase when compared with the secretory

phase. Kuang et al. in a retrospective study of 67 healthy premenopausal women on a 3-T magnet reported higher ADC for the endometrium during the midproliferative/midsecretory phase in women in their 30s than in their 20s and 40s, concluding that age factor should be taken into consideration when interpreting uterine pathology [23]. The increased ADC for normal endometrium in the women in their 30s is probably related to the highest secretion of estrogen, progesterone, and gonadotropins [23]. For each age group, the authors reported lower ADC for the endometrium during the midproliferative phase than during the midsecretory phase, and this is in accordance with our results [23]. In the present study, the ADC of the normal myometrium was lower during the proliferative phase than during the menstrual and the secretory phase. A higher ADC for the myometrium was found during the menstrual phase when compared with the other phases of the menstrual cycle, and this was also seen in our previous report [22].

In this series, we measured and compared the ADC of the normal uterine zones in postmenopausal and repro-

ductive age women. To our knowledge, such a comparative study has not been previously reported. Our findings demonstrated a lower ADC for normal endometrium during menopause when compared with the secretory phase of healthy women. In reproductive age group, the normal endometrium consists of a single layer of columnar epithelium set in a highly vascular cellular stroma [25-27]. Simple tubular glands, thick walled arteries, lymphocytes and lymphoid aggregates are present. The premenopausal endometrium is composed of a thin basal layer (basalis), in proximity to the myometrium, and a functional layer, highly responsive to hormonal ovarian influence. The stroma of the basal layer is more cellular than that of the functional layer, with high nucleocytoplasmic ratios. [25-27]. In postmenopausal women, the endometrium becomes thin and atrophic, with loss of the functional layer, fewer endometrial glands without any proliferative or secretory activity and with increase of the fibrous connective tissue in the endometrial stroma [25-28].

Since the endometrium is thin during menopause, endometrial biopsy samples are often scanty, depicting sparse remnants of narrow endometrial glands lined by a low epithelium with small inactive nuclei and supported by a dense fibrous stroma [25-28]. The above changes probably account for the lower ADC seen in normal postmenopausal endometrium, when compared to the secretory phase of the menstrual cycle. On the other hand, during the secretory phase the functional layer of the endometrium thickens, with the uterine glands becoming larger and wavy and the arteries more prominent [25-28]. The increase of the interstitial fluid in the basal layer during this phase and the lower number of cells may represent other possible explanation for the higher ADC of the endometrium during the secretory phase.

During the menstrual phase, periodic contractions of the walls of the uterine arteries, ischemia and necrosis of the functional layer are followed by rupture of the blood vessels and presence of blood into the endometrial stroma and into the uterine lumen, accompanied by the detached debris of the endometrium [25-28]. The menstrual discharge consisting of blood, stromal tissue and glandular secretions probably account for the restricted diffusion of the normal endometrium during the menstrual phase when compared with the other phases, including the menopause [25-28].

No significant difference was seen between the ADC

of the normal endometrium during menopause and the proliferative phase in the present report. It has been found that there is a proportion of postmenopausal endometria which, despite being atrophic, retain a weak proliferative pattern for many years, probably due to a response to continuous low-level oestrogenic stimulation [29-31]. Sivridis et al. in a histopathologic study of 84 normal endometria from asymptomatic postmenopausal women who undergone hysterectomy for uterus prolapse, reported in at least half of atrophic endometria a proliferative pattern, both diffuse and focal [29]. The same authors speculated that these weakly proliferative endometria have a latent, although very small carcinogenic potential, while atrophic or inactive endometria probably have no potential for tumor growth [29]. Previous studies from endometrial biopsies and curettage specimens reported proliferative activity in approximately 25% of asymptomatic postmenopausal endometria [30-31]. These remarks could probably represent the explanations for the relatively less important decrease of the ADC observed during the menopause when compared with the proliferative phase of the menstrual cycle and might suggest that a high ADC in a postmenopausal endometrium could serve as an alarming sign for the potential development of endometrial cancer.

The myometrium is a thick layer, representing the main bulk of the uterine wall [28]. In both age groups, the myometrium is composed of interlacing bundles of long and slender fibres arranged in ill-defined layers [28]. In postmenopausal women, the myometrium is thin, fibrous and atrophic [28]. These atrophic changes related to atrophy of the muscle fibres and increase in fibrous connective tissue probably explain the decrease of ADC of the normal myometrium observed during menopause.

There are some limitations inherent in the present study. The first is its retrospective design, which resulted in limited clinical information, such as laboratory findings, including hormone levels, clinical symptoms and detailed patient's history, including possible co-morbidities and the use of medications other than oral contraceptives and hormonal replacement therapy. Secondly, only calculations of the ADC of the normal endometrium/myometrium were performed, excluding the junctional zone. Studies measuring the ADC of the normal junctional zone and possible variations with menstrual status are needed. Another potential criticism is the lack of histologic confirmation of the so-called 'normal uter-

ines zones'. In this study, we examined DWI using two  $b$  values of 0 and 800 s/mm<sup>2</sup>; to improve the accuracy of the ADC calculation, it will be necessary to conduct a study with multiple  $b$  values, both low and high. Reproducibility of obtaining DWI was not evaluated in this report. Furthermore, MRI interpretation data were performed by two radiologists in consensus, so interobserver reliability was not assessed.

In concluding, a wide variation of the ADC of normal endometrium/myometrium was observed between menopause and different phases of the menstrual cycle in reproductive age women. The mean ADC ( $\times 10^{-3}$  mm<sup>2</sup>/s) of the normal endometrium and myometrium during menopause was  $1.36 \pm 0.18$  and  $1.60 \pm 0.15$ , respectively. The

mean ADC ( $\times 10^{-3}$  mm<sup>2</sup>/s) of the normal endometrium on reproductive age was  $1.24 \pm 0.22$ ,  $1.38 \pm 0.20$  and  $1.50 \pm 0.18$  during the menstrual, the proliferative and the secretory phase, respectively. The normal ADC ( $\times 10^{-3}$  mm<sup>2</sup>/s) of the myometrium in premenopausal women was  $1.92 \pm 0.28$ ,  $1.72 \pm 0.24$  and  $1.86 \pm 0.27$  during the three phases of menstrual cycle. MR imaging, including DWI represents a valuable tool for examining uterine diseases. It is important for radiologists when interpreting uterine pathology to know the ADC of the normal uterine zones for a physiologic state, including menstrual cycle and aging. **R**

**Conflict of interest:**

The authors declared no conflicts of interest.

## REFERENCES

1. Bammer R. Basic principles of diffusion-weighted imaging. *Eur J Radiol* 2003; 45(3): 169-184.
2. Thoeny HC, Forstner R, De Keyzer F. Genitourinary applications of diffusion-weighted MR imaging in the pelvis. *Radiology* 2012; 263(2): 326-342.
3. Punwani S. Diffusion weighted imaging of female pelvic cancers: concepts and clinical applications. *Eur J Radiol* 2011; 78(1): 21-29.
4. Sala E, Rockall AG, Freeman SJ, et al. The added role of MR imaging in treatment stratification of patients with gynecologic malignancies: What the radiologist needs to know. *Radiology* 2013; 266(3): 717-740.
5. Sala E, Rockall A, Kubik-Huch RA. Advances in magnetic resonance imaging of endometrial cancer. *Eur Radiol* 2011; 21(3): 468-473.
6. Sala E, Rockall A, Rangarajan D, et al. The role of dynamic contrast-enhanced and diffusion weighted magnetic resonance imaging in the female pelvis. *Eur J Radiol* 2010; 76(3): 367-385.
7. Inada Y, Matsuki M, Nakai G, et al. Body diffusion-weighted MR imaging of uterine endometrial cancer: Is it helpful in the detection of cancer in nonenhanced MR imaging? *Eur J Radiol* 2009; 70(1): 122-127.
8. Rechichi G, Galimberti S, Signorelli M, et al. Myometrial invasion in endometrial cancer: Diagnostic performance of diffusion-weighted MR imaging at 1.5-T. *Eur Radiol* 2010; 20(3): 754-762.
9. Cao K, Gao M, Sun YS, et al. Apparent diffusion coefficient of diffusion weighted MRI in endometrial carcinoma-Relationship with local invasiveness. *Eur J Radiol* 2012; 81(8): 1926-1930.
10. Hori M, Kim T, Onishi H, et al. Endometrial cancer: Preoperative staging using three dimensional T2-weighted turbo spin-echo and diffusion-weighted MR imaging at 3.0 T: A prospective comparative study. *Eur Radiol* 2013; 23(8): 2296-2305.
11. Andreano A, Rechichi G, Rebora P, et al. MR diffusion imaging for preoperative staging of myometrial invasion in patients with endometrial cancer: A systematic review and meta-analysis. *Eur Radiol* 2014; 24(6): 1327-1338.
12. Rechichi G, Galimberti S, Signorelli M, et al. Endometrial cancer: Correlation of apparent diffusion coefficient with tumor grade, depth of myometrial invasion, and presence of lymph node metastases. *AJR Am J Roentgenol* 2011; 197(1): 256-262.
13. Fujii S, Matsusue E, Kigawa J, et al. Diagnostic accuracy of the apparent diffusion coefficient in differentiating benign from malignant uterine endometrial cavity lesions: initial results. *Eur Radiol* 2008; 18(2): 384-389.
14. Tamai K, Koyama T, Saga T, et al. The utility of diffusion-weighted MR imaging for differentiating uterine sarcomas from benign leiomyomas. *Eur Radiol* 2008; 18(4): 723-730.



15. Sato K, Yuasa N, Fujita M, et al. Clinical application of diffusion-weighted imaging for preoperative differentiation between uterine leiomyoma and leiomyosarcoma. *Am J Obstet Gynecol* 2014; 210(4): 368.e1-8.
16. Thomassin-Naggara I, Dechoux S, Bonneau C, et al. How to differentiate benign from malignant myometrial tumours using MR imaging. *Eur Radiol* 2013; 23(8): 2306-2314.
17. Takeuchi M, Matsuzaki K, Nishitani H. Manifestations of the female reproductive organs on MR images: Changes induced by various physiologic states. *Radiographics* 2010; 30(4): 1147.
18. Lee JK, Gersell DJ, Balfe DM, et al. The uterus: *In vitro* MR-anatomic correlation of normal and abnormal specimens. *Radiology* 1985; 157(1): 175-179.
19. Demas BE, Hricak H, Jaffe RB. Uterine MR imaging: Effects of hormonal stimulation. *Radiology* 1986; 159(1): 123-126.
20. Haynor DR, Mack LA, Soules MR, et al. Changing appearance of the normal uterus during the menstrual cycle: MR studies. *Radiology* 1986; 161(2): 459-462.
21. Kido A, Kataoka M, Koyama T, et al. Changes in apparent diffusion coefficients in the normal uterus during different phases of the menstrual cycle. *Br J Radiol* 2010; 83(990): 524-528.
22. Tsili AC, Argyropoulou MI, Tzarouchi L, et al. Apparent diffusion coefficient values of the normal uterus: Interindividual variations during menstrual cycle. *Eur J Radiol* 2012; 81(8): 1951-1956.
23. Kuang F, Ren J, Huan Y, et al. Apparent diffusion coefficients of normal uterus in premenopausal women with 3.0-T magnetic resonance imaging. *J Comput Assist Tomogr* 2012; 36(1): 54-59.
24. He Y, Ding N, Li Y, et al. 3-T diffusion tensor imaging (DTI) of normal uterus in young and middle-aged females during the menstrual cycle: Evaluation of the cyclic changes of fractional anisotropy (FA) and apparent diffusion coefficient (ADC) values. *Br J Radiol* 2015;88(1049): 20150043.
25. Dallenbach-Hellweg G, Schmidt D, Dallenbach F. Normal endometrium. In: Dallenbach-Hellweg G, Schmidt D, Dallenbach F (eds). *Atlas of Endometrial Histopathology*. Berlin Heidelberg 2010; 7-44.
26. Dallenbach-Hellweg G. The normal histology of the endometrium. In: Dallenbach Hellweg G (ed). *Histopathology of the endometrium*. Berlin Heidelberg 2013; 20-76.
27. Jiménez-Ayala M, Jiménez-Ayala Portillo B. Cytology of the Normal Endometrium Cycling and Postmenopausal. In: Jimenez-Ayala M, Jimenez-Ayala Portillo B (eds). *Endometrial Adenocarcinoma: Prevention and early diagnosis*. Basel S Karger AG 2008; 32-36.
28. Dutta M, Talukdar KL. A histological study of uterus in reproductive and postmenopausal women. *NJCA* 2015; 4: 17-25.
29. Sivridis E, Giatromanolaki A. Proliferative activity in postmenopausal endometrium: The lurking potential for giving rise to an endometrial adenocarcinoma. *J Clin Pathol* 2004; 57(8): 840-844.
30. Archer DF, McIntyre-Seltman K, Wilborn WW Jr, et al. Endometrial morphology in asymptomatic postmenopausal women. *Am J Obstet Gynecol* 1991; 165(2): 317-320.
31. Korhonen MO, Symons JP, Hyde BM, et al. Histologic classification and pathologic findings for endometrial biopsy specimens obtained from 2,964 perimenopausal and postmenopausal women undergoing screening for continuous hormones as replacement therapy (CHART 2 Study). *Am J Obstet Gynecol* 1997; 176(2): 377-380.



READY - MADE  
CITATION

Tsili A C, Ntorkou A, Vrekoussis T, Maliakas V, Argyropoulou M I. Variations of ADC of normal uterine zones in postmenopausal and reproductive women. *Hell J Radiol* 2016; 1(1): 37-45.