

# Clinical outcome and safety of percutaneous Radiopaque Gelified Ethanol injection in patients with persisting lumbar disc herniation

Stavros Charalambous<sup>1</sup>, Adam Hatzidakis<sup>1</sup>, Konstantinos Spanakis<sup>1</sup>, Andreas Yannopoulos<sup>2</sup>,  
Despo Ierodiakonou<sup>3</sup>, Apostolos Karantanas<sup>1</sup>

<sup>1</sup>Department of Medical Imaging, University Hospital and Medical School, University of Crete, Heraklion, Greece

<sup>2</sup>Department of Neurosurgery, University Hospital, Heraklion, Greece

<sup>3</sup>Department of Social Medicine, Medical School, University of Crete, Heraklion, Greece

SUBMISSION: 5/6/2019 | ACCEPTANCE: 09/11/2019

## ABSTRACT

**Purpose:** To investigate the efficacy and safety of radiopaque gelified ethanol (RGE) injection in patients with medium to large size intervertebral lumbar disc hernias including cases requiring alternative access routes.

**Material and Methods:** Between December 2014 and June 2018, twenty-five patients (14 males, 11 females, median age 52 years (min 21-max 90 years)), were treated for equal number of intervertebral disc hernias by

means of RGE injection under computed tomography (CT)-guidance. All patients were free from neurologic deficits and reported low back pain resistant to conservative treatment for at least six weeks. Pre- and post- treatment pain was evaluated using a visual analogue scale (VAS) score and the VAS difference pre- and post- (6 months) treatment was tested with Wilcoxon matched-pair signed-rank test. Patients were then cate-



### CORRESPONDING AUTHOR, GUARANTOR

**Corresponding author:** Stavros Charalambous, MD, Resident in Radiology, Department of Medical Imaging, University Hospital, University Street, 71500 Stavrakia-Heraklion, Crete, Greece, E-mail: st.charalambous@hotmail.com

**Guarantor:** Apostolos Karantanas, MD, PhD. Professor of Radiology, Department of Medical Imaging, University Hospital, University Street, 71500 Stavrakia-Heraklion, Crete, Greece, E-mail: akarantanas@gmail.com

gorised into groups according to % change in VAS (poor (0%), good (1-99%), excellent (100%) pain response). The association of results with quality of life (QoL) (high vs. low) was assessed using the Fisher's exact test.

**Results:** At the end of the 6-month follow up, pain was significantly improved (mean (SD) in VAS was dropped from 8.1 (1.26) to 3.1 (3.10); mean (95% CI) decrease 5.0

(3.6, 6.4) ( $p < 0.001$ )). Pain response to treatment was excellent in 8 (32%) patients, good in 11 (44%) and poor in 6 (24%) and was significantly associated with the QoL ( $p < 0.001$ ).

**Conclusions:** Percutaneous CT-guided intradiscal RGE injection is safe, easy to handle and offers good therapeutic outcome with better QoL.



## KEY WORDS

Disc herniation; Percutaneous treatment; Radiopaque gelified ethanol; Computed Tomography/guided treatment; MR imaging/diagnosis

### Introduction

Intervertebral disc herniation (IDH) is a common cause of low back pain (LBP) and sciatica, often associated with lower limb weakness [1]. IDH represents an important public health problem since about 70% of general population will experience at least one episode throughout life [2-6]. Multiple therapies are available to treat herniated discs ranging from conservative methods (medication and physiotherapy) to minimal invasive treatment and surgery.

Regardless of the treatment method, a literature review shows that the pain level due to sciatica may not significantly improve over a five-year period [3]. Reduction of intradiscal pressure has been associated with reduced nerve root irritation and thus with symptom relief and improvement of mobility and quality of life (QoL) [7]. Radiopaque gelified ethanol (RGE-“Discogel®”, Gelscom, France) is a chemo-nucleolytic agent, consisting of ethanol mixed with ethyl cellulose and tungsten. RGE acts by causing necrosis and dehydration of nucleus pulposus, thus resulting in retraction of the herniated disc [8].

There is not extensive evidence in the literature related to the clinical outcome and safety of this procedure describing how to overcome difficulties regarding needle access to the disc [9, 10]. Our purpose is to report a single center experience, first discussing the efficacy and safety of this relatively new minimal invasive therapeutic method of percutaneous administration of RGE in patients with LBP of discogenic origin and secondly to present alternative puncture routes in specific circumstances.

### Material and Methods

#### Study population

Twenty-five patients with lumbosacral pain due to disc

herniation, resistant to conservative treatment of at least six weeks, were prospectively selected for treatment with percutaneous intradiscal injection of RGE between December 2014 and June 2018. **Table 1** presents population characteristics. Median (IQR) population age was 52 (40.5, 65.5) years (min 21 - max 90 years), 14 (56%) patients were males and 11 (44%) were females. Disc herniation was found at L3-L4 level in 1 (4%), at L4-L5 level in 17 (68%) and at L5-S1 level in 7 (28%) of the patients.

#### Eligibility criteria

Patient selection was performed with consensus of an experienced Interventional Radiologist who performed the procedure and a Musculoskeletal Radiologist who assessed the Magnetic Resonance Imaging (MRI) examinations.

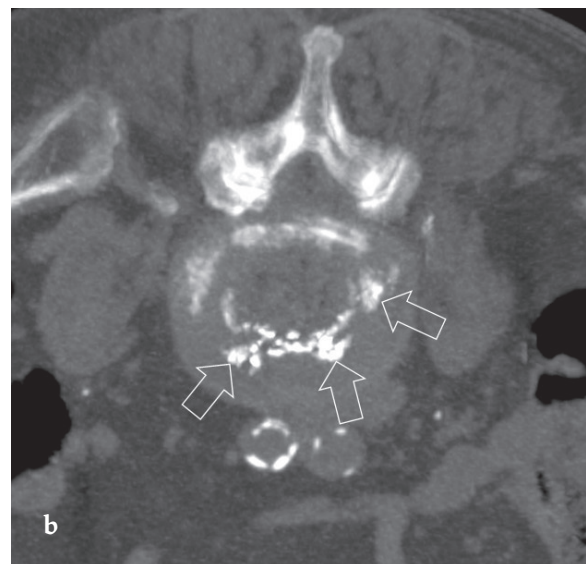
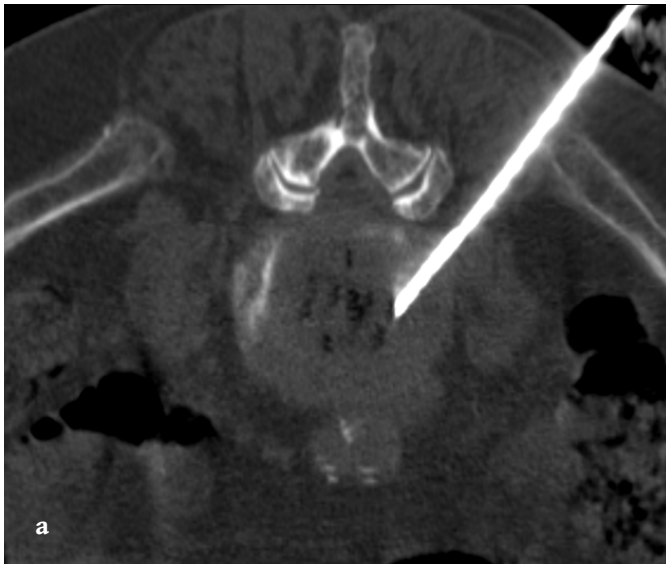
The inclusion criteria in this study were, according to MSU Classification, small to medium sized ( $n=20$ ) herniated intervertebral disc (grade 1 and 2, respectively), confirmed by MRI, with limited routine activity for at least 6 weeks, resistant to conservative treatment (bed rest, analgesics, anti-inflammatory drugs, muscle relaxants and physiotherapy) [11]. The MSU classification takes into account both the size of disc herniation and its location within the various constraints posed by the local anatomy. It employs a single intra-facet line as a reference point to measure the disc herniation at the level of maximum extrusion, based on T2W MR images [11]. Five more patients underwent RGE injection, two ( $n=2$ ) with a large extruded IDH (grade 3), one posterior and one postero-lateral, because they refused to undergo surgical resection and three patients ( $n=3$ ) with disc degeneration-vacuum phenomenon due to poor therapeutical alternatives.

Exclusion criteria for RGE injection were active local or

Table 1. Population characteristics	
Age; median (IQR)	52 (40.5, 65.5)
Males; n (%), Females; n (%)	14 (56), 11 (44)
Level of hernias; n (%)	
L3-L4	1 (4)
L4-L5	17 (68)
L5-S1	7 (28)
Symptoms duration; median (IQR) months	3 (1.5, 12.0)

IQR: interquartile range (25th, 75th)

Table 2. Interpretation of quality of life	
Very good	Patient can cope with most living activities.
Good	Patient experience pain and difficulty with sitting, lifting and standing; may be disable from work; daily lifestyle is affected.
Bad	Pain is the main problem; daily living activities are strongly affected.
Very bad	Pain impinges on all aspects of patient's life.
Disabled	Patient is either bed-bound or exaggerating symptoms.



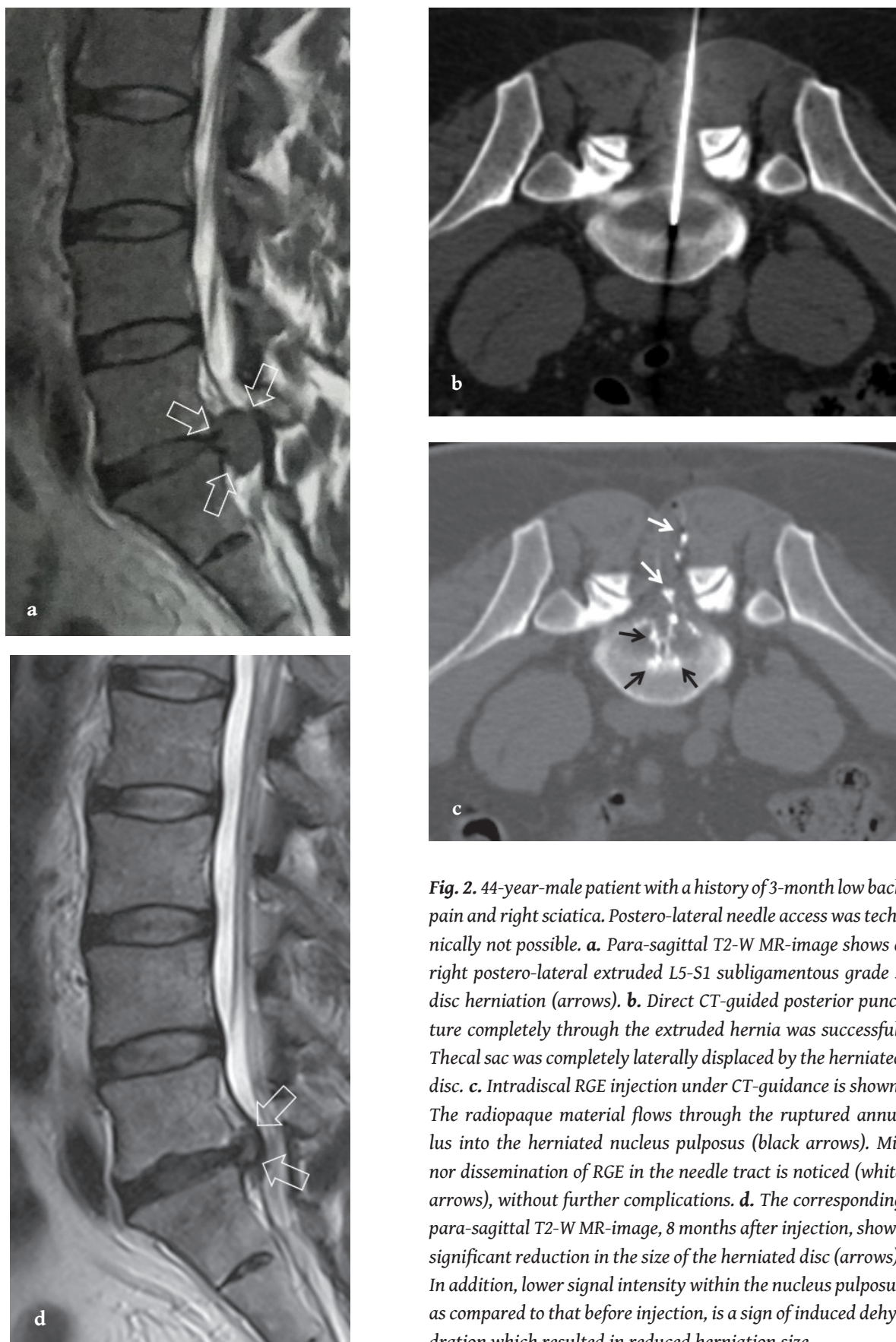
**Fig. 1.** 90-year-old patient with L5-S1 disc hernia causing central stenosis of the spinal canal and low back pain without any evidence of spinal instability or osteoporotic fracture. **a.** CT shows successful postero-lateral puncture of the degenerative disc. **b.** Following the RGE injection, CT shows the normal distribution of the radiopaque material (arrows).

systemic infections/discitis, sequestered disc fragment, severe lateral/foraminal or central spinal canal stenosis, spondylolisthesis, primary tumour or metastatic disease involving the level to be treated, pregnancy, haemorrhagic diathesis and anticoagulation therapy.

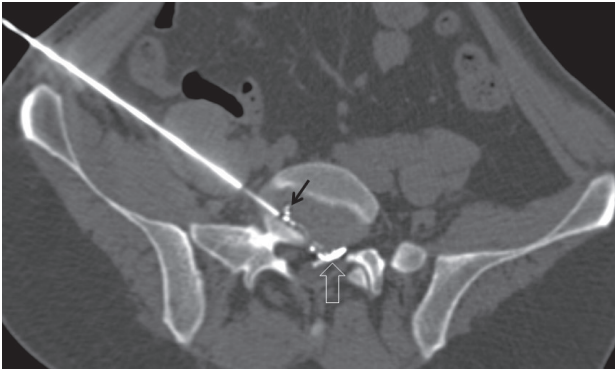
All patients met the criterion for absolute matching of the imaging with the clinical findings, established with consensus by the Interventional and Musculoskeletal Radiologists involved in this study. Our study was conducted according to the principles of Helsinki's Declaration and all patients signed an informed consent. The ethics committee of our hospital approved our study's protocol.

### Procedure and Techniques

In all patients, recent plain films and MRI were obtained. Procedures were performed in aseptic conditions with appropriate preparation, including skin area disinfection with iodine solution. Short-term broad spectrum intravenous antibiotic prophylaxis including 2 g of amoxicillin/clavulanic acid was administered one hour prior to injection. All procedures were performed under CT-guidance with local skin and soft tissue anaesthesia (subcutaneous 1-2 ml lidocaine 2%) and patients in prone position with a pillow under their abdomen (n=24) and in supine position (n=1). Using postero-lateral approach (**Fig. 1a**) in 23 pa-



**Fig. 2.** 44-year-male patient with a history of 3-month low back pain and right sciatica. Postero-lateral needle access was technically not possible. **a.** Para-sagittal T2-W MR-image shows a right postero-lateral extruded L5-S1 subligamentous grade 3 disc herniation (arrows). **b.** Direct CT-guided posterior puncture completely through the extruded hernia was successful. Thecal sac was completely laterally displaced by the herniated disc. **c.** Intradiscal RGE injection under CT-guidance is shown. The radiopaque material flows through the ruptured annulus into the herniated nucleus pulposus (black arrows). Minor dissemination of RGE in the needle tract is noticed (white arrows), without further complications. **d.** The corresponding para-sagittal T2-W MR-image, 8 months after injection, shows significant reduction in the size of the herniated disc (arrows). In addition, lower signal intensity within the nucleus pulposus as compared to that before injection, is a sign of induced dehydration which resulted in reduced herniation size.



**Fig. 3.** 41-year-old male patient with a 3-month history of low back pain and left sciatica. Postero-lateral puncture was not possible. Antero-lateral, extraperitoneal needle access with successful intradiscal injection is shown (black arrow). Minor epidural extensions of the injected material are also shown (open arrow).

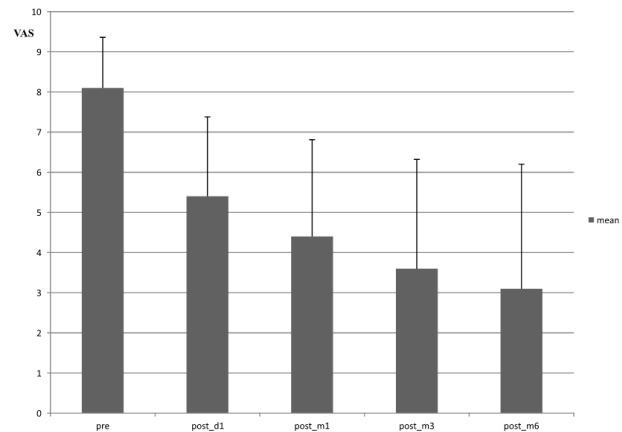
tients, posterior in 1 (**Fig. 2b**) and antero-lateral approach (**Fig. 3**) in 1 patient, an 18 G needle of 15 cm length was inserted aiming the center of the herniated disc. In cases of antero-lateral or postero-lateral hernias, the needle entrance was always through the contralateral to the herniated disc side. After positioning the needle tip inside the nucleus pulposus, 0.9 ml of RGE was slowly injected (about 0.1 ml every 5 seconds). After the injection, a CT scan followed in all cases for access leakage or other potential complications. We treated a total of 25 discs.

In one patient (44 years-old, male) with a large grade 3 extruded L5-S1 disc herniation, postero-lateral access was not possible and the needle was advanced mid-dorsally through the hernia itself, since the thecal sac was laterally displaced (**Fig. 2**). In a second patient (41 years-old, male), L5-S1 disc puncture was not possible in the prone position and the needle was guided through a lateral, extraperitoneal access route with the patient in supine position (**Fig. 3**).

Once the procedure was completed, patients were followed for 4 hours on their bed and then they were discharged after clinical examination. Non-steroid anti-inflammatory drugs and muscle relaxants were prescribed for 7-10 days.

### Assessment of pain and quality of life

Pain intensity and QoL were initially assessed during clinical examination, the morning after the procedure, as well as 1, 3 and 6 months later, via phone interview. Pain sever-



**Fig. 4.** Mean and standard deviation (SD) of Visual Analogue Scale (VAS) scores pre- and post- treatment. Gradual improvement of pain post treatment.

ity was evaluated using a Visual Analogue Scale (VAS 0-10) score and functionality status (QoL) was graded based on a 5-item response (**Table 2**) as very good, good, bad, very bad or disabled. The pain response to treatment was measured as % change pre-post VAS score ( $100 \times (\text{pre} - \text{post}) / \text{pre}$ ) was classified as excellent (100%), good (1-99%) or poor (0%). The QoL was further grouped as high (very good & good) and low (bad, very bad or disabled).

### Statistics

Descriptive statistics were presented as count (percentage (%)) or median (interquartile range (IQR)). We tested for change (pre-post) in pain VAS score with Wilcoxon matched-pair signed-rank test, and we used the Fisher's exact test to assess association of pain response to treatment with QoL at 6 months. A p-value of <0.05 was considered to indicate statistically significant associations. Data management and statistical analyses were performed using IBM-SPSS Statistics software (version 23).

### Results

Pain and QoL pre and post treatment are shown in **Table 3** and **Fig. 4**. Pain on the following morning as well as at one, three and six months after RGE injection was significantly lower compared to prior to the procedure (p-values <0.05; **Table 4**). Pain response to treatment at the end of the follow up was excellent in 8 patients (32%), good in 11 (44%) and poor in 6 (24%), and QoL was high in 18 (72%) patients (**Table 5**). High QoL was found in all patients (100%) with

**Table 3. Pain and quality of life pre- and post- treatment**

	Pre	Post day 1	Post 1 <sup>st</sup> month	Post 3 <sup>rd</sup> month	Post 6 <sup>th</sup> month
<b>Pain (VAS)</b>					
Mean (SD)	8.1 (1.26)	5.4 (1.98)	4.4 (2.41)	3.6 (2.72)	3.1 (3.10)
Median (IQR)	8.0 (7.0, 9.0)	6.0 (4.5, 6.0)	5.0 (3.0, 5.5)	3.0 (2.0, 5.5)	2.0 (0.0, 5.5)
<b>Quality of life; n (%)</b>					
Very good	0	3 (12)	4 (16)	10 (40)	14 (56)
Good	0	3 (12)	7 (28)	5 (20)	4 (16)
Bad	2 (8)	10 (40)	10 (40)	5 (20)	1 (4)
Very bad	13 (52)	7 (28)	2 (8)	3 (12)	4 (16)
Disabled	10 (40)	2 (8)	2 (8)	2 (8)	2 (8)

IQR: interquartile range (25th, 75th), SD: standard deviation, VAS: visual analogue scale

**Table 4. Pain improvement (VAS) post treatment**

	Mean Decrease* (95%CI)	p-value#
1 <sup>st</sup> day post treatment	2.7 (1.9, 3.5)	<0.001
1 <sup>st</sup> month post treatment	3.7 (2.7, 4.7)	<0.001
3 <sup>rd</sup> month post treatment	4.4 (3.2, 5.6)	<0.001
6 <sup>th</sup> month post treatment	5.0 (3.6, 6.4)	<0.001

# Wilcoxon matched-pair signed-rank test

VAS: visual analogue scale, 95% CI: 95% confidence interval

\*change=pre treatment VAS score - post treatment VAS score

excellent response, in 10 (90.9%) with good and none with poor response (p-values <0.05; **Table 6**).

The only minor complication in our study was a small extradiscal epidural leakage, noticed in 2 cases (n=2; 8%) based on the CT findings after RGE injection, without any clinical sequelae. No major complications related to treatment or allergic reactions to RGE occurred. In 6 cases with unhelpful results, post- treatment MRI was performed due to persistent symptoms or on scheduled follow-up basis at 3 months time.

### Discussion

Disc herniation is one of the most common sources of LBP [12]. Regardless of the treatment method, pain intensity, as well as impaired function and mobility, may persist up to a 5-year period [3]; thus, any treatment option should aim at high clinical response with low complication rates. According to the “Quality Assurance Guidelines” for per-

**Table 5. Therapeutic outcome at the end of follow-up**

<b>Pain response to treatment; n (%)</b>	
Excellent	8 (32)
Good	11(44)
Poor	6 (24)
<b>Quality of life; n (%)</b>	
High	18 (72)
Low	7 (28)

**Table 6. Pain improvement (VAS) post treatment**

	Quality of Life* (at 6 months)		p-value <sup>1</sup>
Pain response to treatment (at 6 months) #	High	Low	
Poor	0	6 (100)	<0.001
Good	10 (90.9)	1 (9.1)	
Excellent	8 (100)	0	

#Pain response to treatment: % change in VAS poor: 0, Good: 1-99%, Excellent: 100%

\*High= very good & good, Low: Bad & very bad & disabled

<sup>1</sup>Fisher's exact test

cutaneous treatment of intervertebral discs, published by the Cardiovascular and Interventional Society in Europe, a wide range of minimally invasive percutaneous methods have been implemented for treatment of symptomatic disc herniation [2]. These techniques refer to image guided procedures, all based on the puncture of the annulus

with a needle or a trocar, through which chemical, thermal or mechanical devices may be inserted inside the nucleus pulposus [13]. RGE injection seems to offer high success rate matched with very low complication rate [14]. Complications described for the use of RGE are systemic allergic reactions to the substance, discitis and neurologic injury [1].

RGE is a viscous solution in ethanol mixed with ethyl-cellulose and tungsten that causes a local dehydration of the nucleus pulposus, resulting in volume loss and retraction of intervertebral disc herniation [1]. Either fluoroscopy or CT can be used for injection, depending on personal preferences and the center's experience. The injection of ethyl-cellulose increases viscosity and therefore restricts the intradiscal ethanol diffusion. In addition, it deposits part of the gel leading to "soft intradiscal prosthesis" [1]. Tungsten makes this "prosthesis" radiopaque and easily recognised by CT or fluoroscopy. In addition, ruptured annulus with small fissures can be monitored when filled with RGE solution (**Fig. 1b, 2c and 3**). Pain improvement may be attributed to dehydration of the nucleus pulposus with subsequent reduction of intradiscal pressure and hernia retraction [1]. The most important intradiscal therapeutic reaction is probably the decrease of pressure allowing partial decompressive shift of herniated nucleus material [1, 15]. This fact may explain rapid symptom improvement despite unchanged volume of disc herniation on initial imaging follow-up.

Three major studies in the literature report the success and complication rates of RGE injection for lumbar disc herniation. Volpentesta et al reported in a group of 72 patients excellent/good results in 80.4%, despite complications in 5.5% [1]. Theron et al in a group of 221 patients reported a success rate of 91.4% and a complication rate of <0.5% [15] whereas Stagni et al did not mention any complications in a group of 32 patients with therapeutic success rate of 75% [16]. In our study, we injected RGE under CT-guidance in 25 patients with lumbosacral pain resistance to conservative treatment for at least 6 weeks and our excellent/good results in response to pain in 76% and high QoL in 72% without any harmful complications are in agreement with the reported results.

We failed to achieve adequate clinical outcome in six patients. In three elderly patients (one female 78- years and two male 82- and 90 years), failure was probably related to the fact that in the heavily degenerative disc the nucle-

us pulposus is less likely to undergo further dehydration. In addition, elderly patients may present with sciatica because of degenerative disease of the apophyseal joints and/or segmental instability leading to an erroneous clinical diagnosis. In the fourth patient (26-year-old, male) we had some clinical response but initial symptoms recurred by the end of follow-up period. Our explanation was that he increased loading in the post-procedure period, despite medical consultation. The last two poor clinical response cases (one male 45-years and one female 70- years) experienced no clinical improvement and were operated six months later. We have no explanation for this clinical outcome despite the successful injection of RGE material.

The gel solution was normally distributed in all cases without any complications. Similar hernias with similar RGE distribution showed variant clinical outcome. Therefore, it may not be possible to predict the post-interventional clinical outcome based alone on the image characteristics of the herniated discs. Future studies with larger number of patients may provide more data on the specific characteristics where some patients do not show the expected clinical improvement.

#### *Needle access route alternatives*

In cases where a postero-lateral needle access is not possible (usually for the L5-S1 disc level puncture) alternative accesses can be proposed, like in two of our cases. In the first one, with a large postero-lateral hernia causing compression and lateral displacement of the thecal sac, direct dorsal puncture was successfully performed without injuring the spinal nerves (**Fig. 2**). In the second case, an antero-lateral extra-peritoneal access was chosen and the long needle could enter the herniated disc from a lateral route (**Fig. 3**). No complications were noted in both patients. Therefore, this alternative pathway should be kept in mind as an option, if conventional puncture is not possible. However, this alternative access is possible only under CT-guidance and not with fluoroscopy, in order to avoid any harmful effects to vital anatomic structures.

The main limitation of our study is the relatively small sample size.

#### *Conclusions*

This study reports our initial experience of intradiscal RGE injection as a minimally invasive treatment of herniated disc, including patients who required an alternative route of access. RGE injection offers good clinical outcomes re-

garding management of LBP of discogenic origin and has a low rate of complications. Treatment was performed as Day cases under local anaesthesia; therefore it does not require hospitalisation with the rare exceptions of serious complications. Our experience is encouraging and in ac-

cordance to the literature results, with no recorded serious side effects. **R**

### **Conflict of interest**

The authors declared no conflicts of interest.

## REFERENCES

1. Volpentesta G, De Rose M, Bosco D, et al. Lumbar percutaneous intradiscal injection of Radiopaque Gelified Ethanol ("Discogel") in patients with low back and radicular pain. *J Pain Relief* 2014; 3(3): 145.
2. Kelekis AD, Fillipiadis DK, Martin JB, et al. Standards of practice: Quality assurance guidelines for percutaneous treatments of intervertebral disc. *Cardiovasc Intervent Radiol* 2010; 33: 909-913.
3. De Seze M, Saliba L, Mazaux JM. Percutaneous treatment of sciatica caused by a herniated disc: An exploratory study on the use of gaseous discography and Discogel in 79 patients. *Ann Phys Rehabil Med* 2013; 56(2): 143-154.
4. Andersson GBJ. Epidemiological features of chronic low-back pain. *Lancet* 1999; 354(9178): 581-585.
5. Valat JP, Genevay S, Marty M, et al. Sciatica. *Best Pract Res Clin Rheumatol* 2010; 24(2): 241-252.
6. Leglise A, Lombard J, Moufid A. Discogel in patients with discal lumbosciatica. Retrospective results in 25 consecutive patients. *Orthop Traumatol Surg Res* 2015; 101: 623-626.
7. Singh V, Derby R. Percutaneous lumbar disc decompression. *Pain Physician* 2006; 9(2): 139-146.
8. Kennedy M. IDET: A new approach to treating lower back pain. *WMJ* 1999; 98(6): 18-20.
9. Theron J, Cuellar H, Sola T, et al. Percutaneous treatment of cervical disk hernias using gelified ethanol. *AJNR Am J Neuroradiol* 2010; 31(8): 1454-1456.
10. Bellini M, Romano DG, Leonini S, et al. Percutaneous injection of radiopaque gelified ethanol for the treatment of lumbar and cervical intervertebral disk herniations: experience and clinical outcome in 80 patients. *AJNR Am J Neuroradiol* 2015; 36(3): 600-605.
11. Mysliwiec LW, Cholewicki J, Winkelpleck MD, et al. MSU Classification for herniated lumbar disc on MRI: toward developing objective criteria for surgical selection. *Eur Spine J* 2010; 19(7): 1087-1093.
12. Eichen PM, Achilles N, Konig V, et al. Nucleoplasty, a minimally invasive procedure for disc decompression: a systematic review and meta-analysis of published clinical studies. *Pain Physician* 2014; 17(2): E149-173.
13. Boswell MV, Trescot AM, Datta S, et al. Interventional techniques: evidence-based practical guidelines in the management of chronic spinal pain. *Pain Physician* 2007; 10(1): 7-111.
14. Chiba K. An experimental study on the pathological changes of the intervertebral disc and its surrounding tissues after intradiscal injection of various chemical substances (the first report). *Nihon Seikeigeka Gakkai Zasshi* 1993; 67(11): 1055-1069.
15. Theron J, Guimaraens L, Casasco A, et al. Percutaneous treatment of lumbar intervertebral disc hernias with radiopaque gelified ethanol: a preliminary study. *J Spinal Disord Tech* 2007; 20(7): 526-532.
16. Stagni S, de Santis F, Cirillo L, et al. A minimally invasive treatment for lumbar disc herniation: Discogel chemonucleolysis in patients unresponsive to chemonucleolysis with oxygen-ozone. *Interv Neuroradiol* 2012; 18(1): 97-104.



READY - MADE  
CITATION

Charalambous S, Hatzidakis A, Spanakis K, Yannopoulos A, Ierodiakonou D, Karantanias A. Clinical outcome and safety of percutaneous Radiopaque Gelified Ethanol injection in patients with persisting lumbar disc herniation. *Hell J Radiol* 2019; 4(4): 10-17.