

## CLINICAL CASE - TEST YOURSELF

## Abdominal Imaging

# Right upper quadrant pain and jaundice in a middle age male patient

Sofia Papaioannou<sup>1</sup>, Elissavet Pazarli<sup>2</sup>, Panos Prassopoulos<sup>3</sup>

<sup>1</sup>Radiology Department, Papageorgiou Hospital, Thessaloniki, Greece

<sup>2</sup>Pathology Laboratory, Papageorgiou Hospital, Thessaloniki, Greece

<sup>3</sup>AHEPA Hospital, Aristoteleion University of Thessaloniki, Greece

SUBMISSION: 27/07/2019 | ACCEPTANCE: 15/12/2019

## PART A

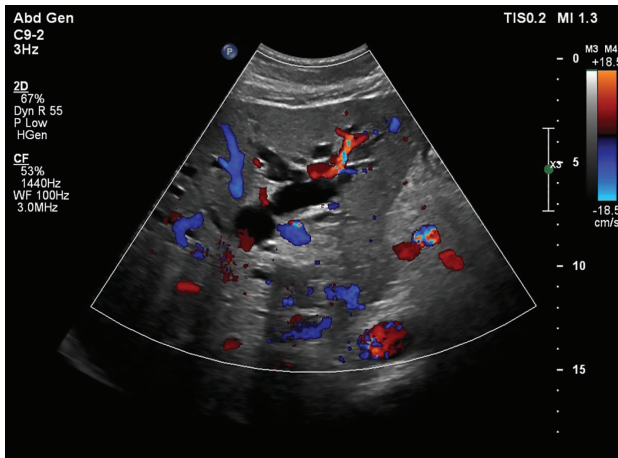A 54-year-old male patient presented to the hospital with a 3-month history of progressively increasing right upper quadrant pain, lately associated with jaundice. A palpable mass was found on physical examination. Laboratory tests included: WBC count 11.9/ $\mu$ L, total bilirubin

7.16 mg/dl, SGOT 40 U/L and  $\gamma$ GT 629U/L. Abdominal ultrasonography (**Fig. 1**) was initially performed, followed by contrast enhanced computed tomography (CT) (**Fig. 2**) and magnetic resonance imaging (MRI) (**Fig. 3**). Biopsy was performed for final diagnosis.

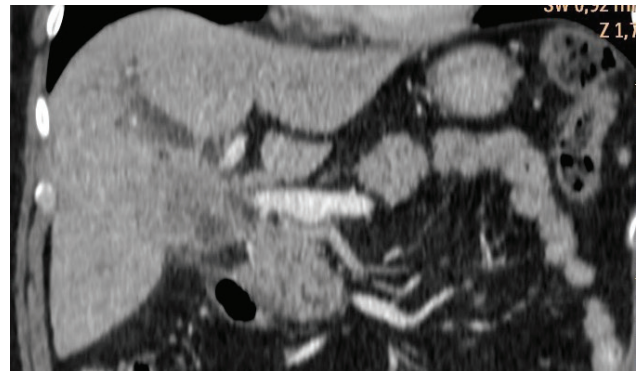


CORRESPONDING  
AUTHOR,  
GUARANTOR

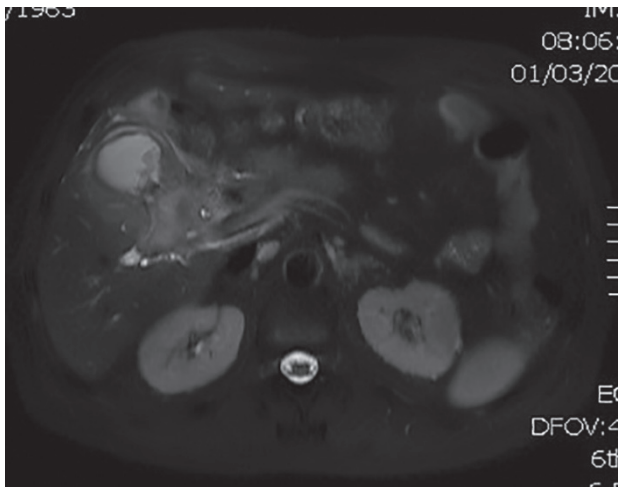
Sofia Papaioannou,  
Radiology Department, Papageorgiou Hospital, Ring Road, N. Eykarpia, 56403,  
Thessaloniki, Greece, Email: sofipapaioannou@gmail.com



**Fig.1.** Liver colour Doppler ultrasonography.



**Fig. 2.** Abdominal coronal contrast-enhanced CT reconstruction.



**Fig. 3.** Abdominal axial T2W MR image with fat saturation.

---

## PART B

---

### **Diagnosis: Gallbladder carcinoma extending to the hepatoduodenal ligament**

Imaging revealed an infiltrative lesion involving the gallbladder and the hepatoduodenal ligament, possibly extending to the groove area between the pancreatic head and the duodenum, as well as biliary obstruction (Figs. 1-3). Locating the exact origin of the neoplasm was difficult. The pancreas was excluded from the very beginning as the pancreatic duct did not show dilatation.

Differential diagnosis included gallbladder tumour, cholangiocarcinoma and adenocarcinoma of the groove area, extending through the hepatoduodenal ligament. These three entities differ in treatment options and prognosis.

Gallbladder carcinoma and cholangiocarcinoma do not usually extend to the groove area. On the other hand, thickening of the gallbladder wall is not a sign of groove adenocarcinoma, but mostly a sign of a gallbladder tumour.

A CT-guided biopsy was performed through the hepatoduodenal ligament. Histology revealed fibrosis and infiltration of low to moderately differentiated adenocarcinoma, either primary or metastatic (Fig. 4). The specimen was CK-7 positive and CK-20 negative (Fig. 5). Adenocarcinomas of the gallbladder, the bile ducts and the pancreas are included in CK7+/CK20- tumours. However, a combined evaluation of all findings indicates adenocarcinoma of the gallbladder.

Gallbladder cancer is an uncommon tumour. Seventy percent of gallbladder malignant neoplasms occur in women [1]. The main predisposing factors are cholelithiasis, chronic biliary infections, primary sclerosing cholangitis and porcelain gallbladder. In our male patient none of those risk factors was present.

Adenocarcinoma accounts for 98% of gallbladder tumours. Laboratory tests are generally non-diagnostic. Serum tumour markers, carcinoembryonic antigen (CEA) and carbohydrate antigen 19-9 (CA 19-9) are frequently elevated [2] but are not specific. The tumour may extend to the adjacent liver parenchyma (liver bed type) and/or the hepatic hilum (hilum type). The latter may manifest with obstructive jaundice [3]. Extension to the groove area through the hepatoduodenal ligament is not a common manifestation.

The initial imaging appearance of a gallbladder carcinoma is a polypoid lesion, seen in 15–25% of cases. Malignant lesions are generally larger than 1 cm in diameter and tend

to have a thickened implantation base. An occupying mass in the gallbladder lumen is present in 40–65% of patients while focal or diffuse asymmetric wall thickening is demonstrated in 20–30% of patients [4].

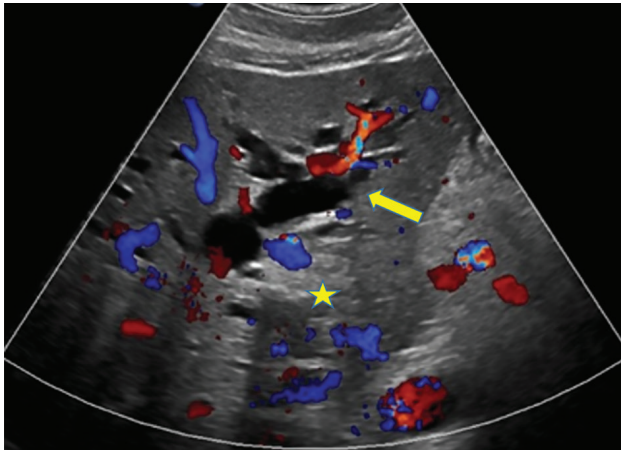
According to the TNM classification of gallbladder tumours [5] a T1a lesion invades the lamina propria, while a T1b lesion invades the muscular layer. The current classification discriminates between the peritoneal and hepatic surfaces involvement, in T2a and T2b, respectively. A T2a tumour invades the perimuscular connective tissue on the peritoneal side, without involvement of the serosa (visceral peritoneum) while a T2b tumour invades the perimuscular connective tissue on the hepatic side, with no extension into the liver. A T3 tumour perforates the gallbladder serosa or infiltrates the liver or one adjacent organ, including stomach, duodenum, colon, pancreas, omentum and extrahepatic bile ducts. T4 tumours invade the main portal vein, hepatic artery, or two or more extrahepatic organs. T1 or T2 primary lesions without lymph node involvement are considered as stage IA or IB disease, respectively. T3 lesions without lymph nodes are characterised as stage IIA. T1, T2, or T3 lesions with N1 (1–3 lymph nodes) involvement are classified as stage IIB. A T4 lesion without distant metastasis is classified as stage III. Any patient with distant is classified as stage IV [6].

The hepatoduodenal ligament may be infiltrated by many malignant lesions, such as pancreatic adenocarcinoma, CBD cholangiocarcinoma or duodenal carcinoma, as well as by inflammatory conditions, such as focal pancreatitis, focal autoimmune pancreatitis and groove pancreatitis, resulting in diagnostic dilemmas. Gallbladder carcinoma may also invade the hepatoduodenal ligament.

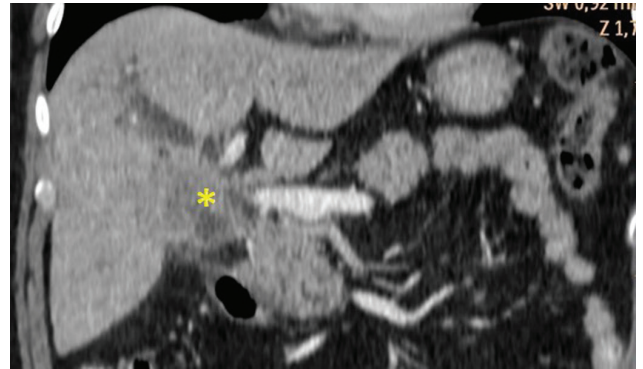
Prognosis depends on the stage rather than on the type of tumour spread [7]. Cases in stage I and II are potentially resectable. On the contrary, stage III suggests locally unresectable disease, due to vascular and/or biliary duct invasion or infiltration of multiple adjacent organs [8]. In stage IV non-resectability is due to distant metastases [9]. In our case the tumour was classified as stage III due to biliary invasion. A sphincterotomy was performed during ERCP and a stent was placed to relieve jaundice. **R**

### **Conflict of interest**

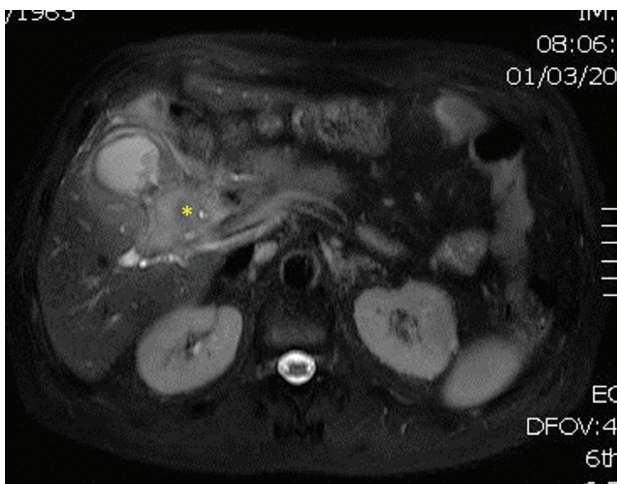
*The authors declared no conflicts of interest.*



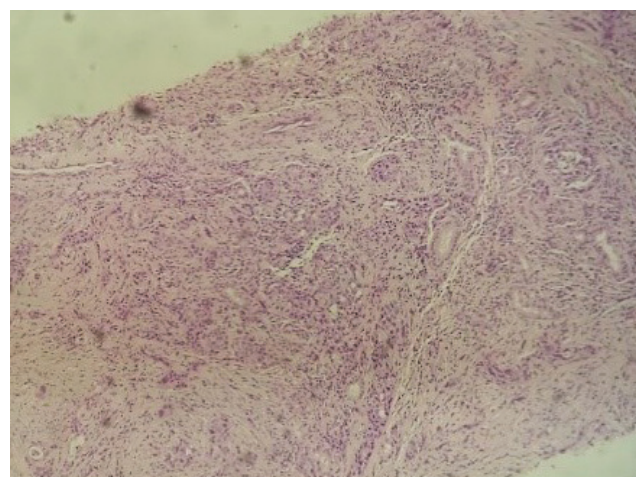
**Fig. 1.** Ultrasonographic image showing dilatation of the intrahepatic bile ducts (arrow) and a hyperechoic mass at the hepatic hilum (asterisk).



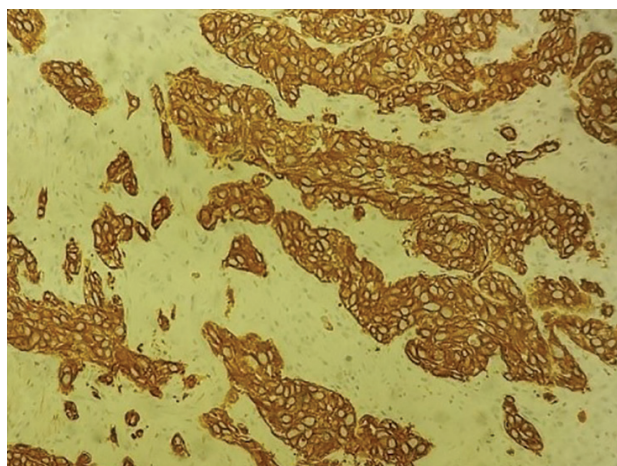
**Fig. 2.** Abdominal coronal contrast-enhanced CT reconstruction shows irregular thickening of the gallbladder wall and extension to the hepatoduodenal ligament (asterisk).



**Fig. 3.** Abdominal axial T2W MR image with fat saturation exhibits thickening of the gallbladder wall, as well as extension and infiltration of the hepatoduodenal ligament (asterisk).



**Fig. 4.** Pathology specimen. Low differentiated neoplastic glandular and compact structures, embedded in a desmoplastic and inflammatory stroma within the wall of the gallbladder (H&E stain  $\times 100$ ).



**Fig. 5.** Pathology specimen. Immunostain showed tumour cells to be strongly positive for cytokeratin CK7 (immunostain CK7  $\times 100$ ).



## KEY WORDS

MR imaging/diagnosis; Computed Tomography/Abdomen; Hepatoduodenal ligament; Gallbladder carcinoma; Cholangiocarcinoma

## REFERENCES

1. Hickman L, Contreras C. Gallbladder cancer diagnosis, surgical management, and adjuvant therapies. *Surg Clin North Am* 2019; 9: 337–355.
2. Narayanswami J, Smith D, Enzerra M, et al. “-Omas” presenting as “-itis”: acute inflammatory presentation of common gastrointestinal neoplasms. *Emerg Radiol* 2019; 26(4): 433-448.
3. Kondo S, Hirano S, Tanaka E, et al. Two types of extended liver resection for advanced gallbladder cancer: How to do it. *Dig Surg* 2011; 28: 148–153.
4. Furlan A, Ferris J, Hosseinzadeh K, et al. Gallbladder carcinoma update: Multimodality imaging evaluation, staging, and treatment options. *AJR Am J Roentgenol* 2008; 191: 1440-1447.
5. Sharma A, Sharma K, Gupta A, et al. Gallbladder cancer epidemiology, pathogenesis and molecular genetics: Recent update. *World J Gastroenterol* 2017; 23(22): 3978-3998.
6. Boutros C, Gary M, Baldwin K, et al. Gallbladder cancer: Past, present and an uncertain future. *Surg Oncol* 2012; 21 (4): e183-e191.
7. Zhou Di, Wang J, Quan Z, et al. Improvement in the diagnosis and treatment of T2 gallbladder carcinoma is pivotal to improvement in the overall prognosis for this disease. *BioSci Trends* 2019; 13(1): 1-9.
8. Sikora SS, Singh R. Surgical strategies in patients with gallbladder cancer: Nihilism to optimism. *J Surg Oncol* 2006; 93(8): 670–681.
9. Hundal R, Shaffer E. Gallbladder cancer: epidemiology and outcome. *Clin Epidemiol* 2014; 6: 99–109.

READY - MADE  
CITATION

Papaioannou S, Pazarli E, Prassopoulos P. Right upper quadrant pain and jaundice in a middle age male patient. *Hell J Radiol* 2019; 5(1): 56-60.