

CLINICAL CASE - TEST YOURSELF Abdominal Imaging

Early IVC opacification: One clue, several paths

Andjoli Davidhi, Christos Christoforidis, Panos Prassopoulos

Department of Radiology, Aristotle University of Thessaloniki, AHEPA Hospital of Thessaloniki, Greece

SUBMISSION: 25/7/2020 | ACCEPTANCE: 28/10/2020

PART A

A 62-year-old, bedridden, male patient was referred to the hospital due to exacerbation of low back pain, lasting for six months. Pain was attributed to lumbar spondylodiscitis - diagnosed by blood culture - which was treated with various combinations of antibiotics. However, the pain never receded.

His clinical examination revealed oedema of lower

extremities, abdominal thrill and bruit. A gradually deteriorating heart and renal failure after a left hemilaminectomy/discectomy at the L4-L5 level, performed a year ago, was reported in the patient's medical history.

A CT examination was requested; the first slices of the CT examination (**Fig. 1a, b**) revealed an imaging sign that can be seen in a wide spectrum of diseases.



CORRESPONDING AUTHOR, GUARANTOR

Corresponding author: Andjoli Davidhi, Department of Radiology, Aristotle University of Thessaloniki, AHEPA Hospital of Thessaloniki, 1 St. Kyriakidi Str., 54636, Thessaloniki, Greece, Email: davidhi-andy@hotmail.com

Guarantor: Panos Prassopoulos, Department of Radiology, Aristotle University of Thessaloniki, AHEPA Hospital of Thessaloniki, 1 St. Kyriakidi Str., 54636, Thessaloniki, Greece, Email: pprasopo@auth.gr

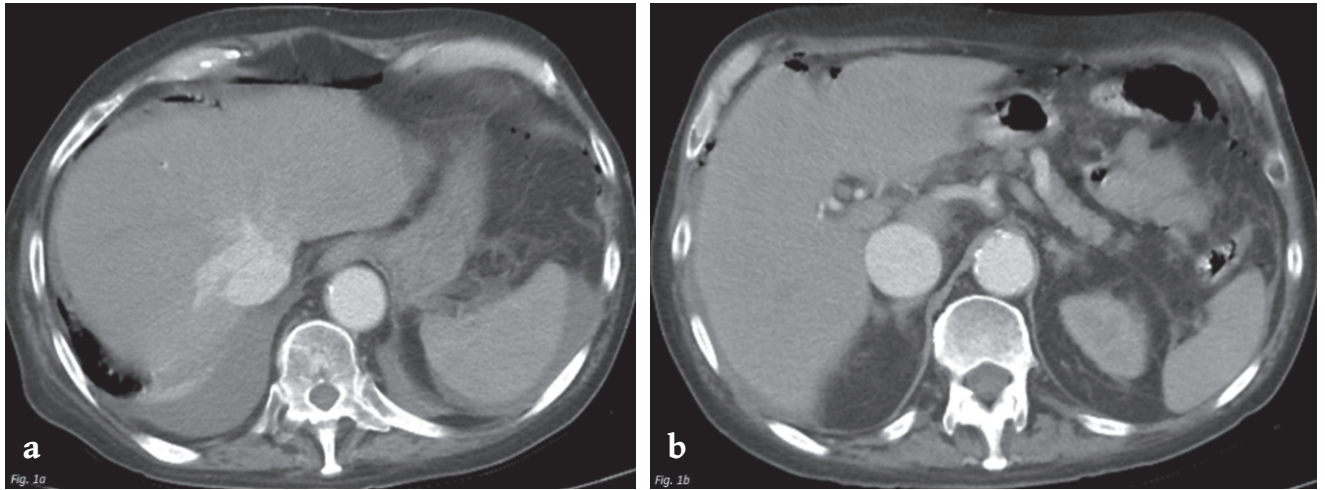


Fig. 1. a. Abdominal contrast enhanced CT, arterial phase at the hepatic veins' level, **b.** Abdominal contrast enhanced CT, arterial phase at the suprarenal level.

PART B

Diagnosis: Iatrogenic common iliac arteriovenous fistula

The early inferior vena cava (IVC) opacification is an imaging sign indicative of various intrathoracic or sub-diaphragmatic disorders.

Intrathoracic causes include right-sided cardiac diseases and superior vena cava obstruction (SVCO). Right-sided cardiac diseases, such as tricuspid regurgitation, carcinoid heart disease (Hedinger syndrome), pulmonary hypertension, or right ventricular systolic dysfunction, may cause right heart failure and high systemic venous pressure. As a result, retrograde flow of blood into IVC occurs and opacification of IVC during the early arterial phase can be observed on CT [1-3]. SVCO is usually caused by direct compression or infiltration of the upper central venous system from a mediastinal or pulmonary mass. Thus, the major collateral pathways between SVC and IVC's, i.e. azygous-hemiazygous and vertebral venous plexus, drain directly into the IVC causing its early opacification [3].

Sub-diaphragmatic causes that may exhibit early enhancement of IVC include hepatic arteriovenous shunting, spontaneous aorto-caval fistulas and iatrogenic arteriovenous fistulas. Hypervascular liver tumours, such as hepatocellular carcinoma, are often responsible for the development of arteriovenous shunting and, consequently, early enhancement of hepatic veins and IVC [2]. Spontaneous aorto-caval fistulas are a rare result of chronic pressure of the IVC by an abdominal atherosclerotic aortic aneurysm complicated by rupture into the IVC. CT reveals early and simultaneous enhancement of both IVC and aorta [3].

Iatrogenic common iliac arteriovenous fistula (IAVF) may demonstrate simultaneous presence of contrast agent in the aorta and IVC during the arterial phase, which is considered to be the most important diagnostic sign for aortocaval or iliac vessels fistulas [4]. Co-existing imaging findings include dilatation of IVC, absence of adipose tissue between iliac vessels or visualisation of the communication, all of which were present in our patient (Figs. 2, 3). In our case, the gradual aggravation of patient's heart and renal failure after a left petalectomy/discectomy at the L4-L5 level, combined with the

imaging findings mentioned above, led to the conclusion of a progressive enlargement of a chronic iliac AVF caused by the operation.

The incidence of arteriovenous communication between the aorto-iliac territory and the IVC is rare, with a reported rate of 0.22% to 2.22% of all abdominal aortic aneurysms [5, 6]. Patients with aortocaval fistula (ACF) or IAVF may be divided into two groups according to the time of presentation of post-traumatic ACF/IAVF: those at the acute phase in the scene of the injury or during emergency surgery; and those at a delayed phase developing symptoms weeks, months or even years after the incident. In the second group, patients usually present heart failure due to the fistula, as in our case [7]. A remarkable amount of oxygenated blood flow is being diverted into the IVC, causing cardiomegaly and high-output congestive cardiac failure, due to the inability of the heart to meet the needs of the organs in O₂.

Typical signs of ACF/IAVF are abdominal pain, pulsatile abdominal mass, abdominal bruit, and acute dyspnoea. Furthermore, signs of peripheral venous congestion, such as lower limb oedema or deep vein thrombosis, may also occur.

Post-traumatic ACF/IAVF accounts for less than 20% of all ACF/IAVFs. In this subgroup, 90% of the cases are related to penetrating injuries or iatrogenic causes (spinal surgery, lumbar disk surgery, arterial catheterisation), while the remaining 10% are secondary to blunt trauma [7]. Vascular injury after disk surgery at the lumbar region is an uncommon, but serious complication. Szolar et al. reported an incidence of 0.05% (4/8,099) of vascular complications arising from lumbar disk surgery [8]. It can be sudden and fatal. The risk of injury to the pelvic vessels intra-operatively can be explained by the proximity of the retroperitoneal vessels to the vertebral bodies. Injury of the anterior longitudinal ligament can give access to the retroperitoneal space. Spinal experts agree that malpositioning of the posterior rongeur is the most frequent cause of injury of the retroperitoneal vessels [9]. Most of the reported cases occurred at the left common iliac artery during an operation either at the L4-L5 level or at the L5-S1 level [10].

There are two main therapeutic options for patients

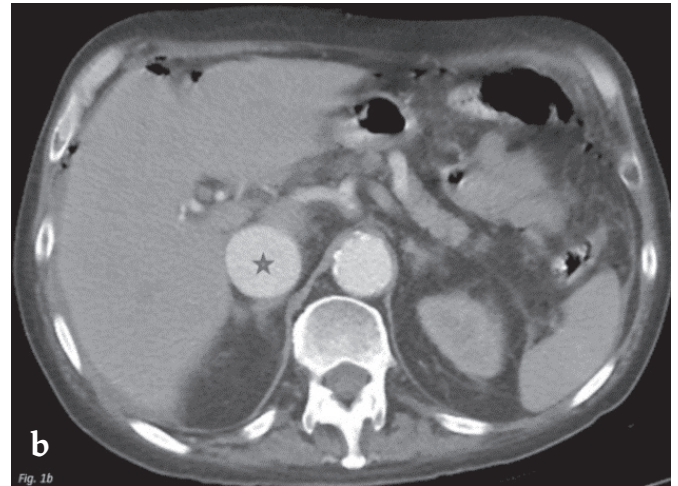
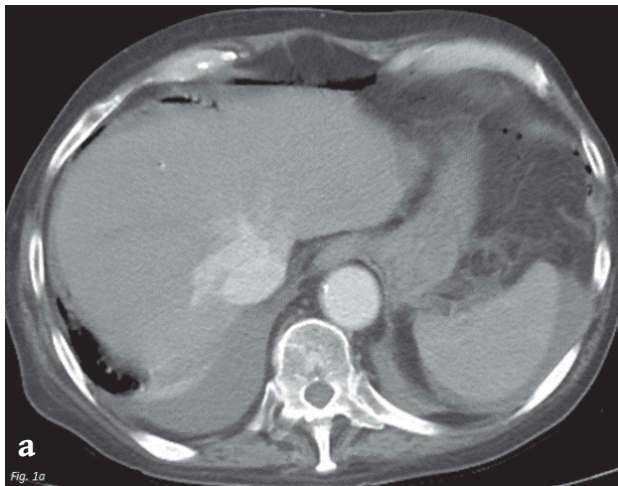


Fig. 1. a. Abdominal contrast enhanced CT, arterial phase at the hepatic veins' level showing synchronous enhancement of both abdominal aorta and IVC, **1b.** Abdominal contrast enhanced CT, arterial phase at the suprarenal level demonstrating simultaneous opacification of abdominal aorta and IVC. Note the excessive dilatation of IVC (asterisk).

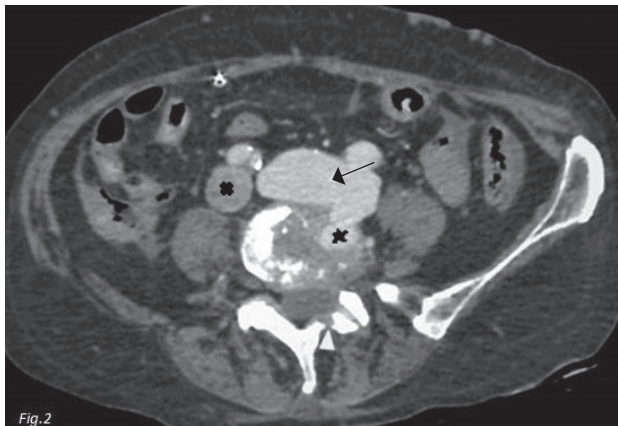


Fig. 2. Abdominal CT, arterial phase, at the L4-L5 level exhibiting simultaneous enhancement of left common iliac artery and vein, marked dilatation of left common iliac vein, loss of adipose tissue between them (arrow) and non-enhancement of right common iliac vein (x), all of which are findings of left common iliac AVF. Note the presence of contrast agent in the intervertebral space (asterisk) and the left hemilaminectomy in the same line with the iliac communication (white arrowhead).

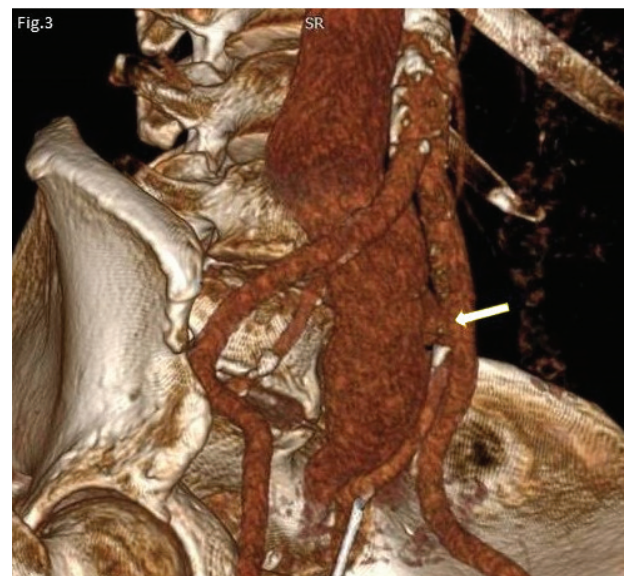

Fig. 3. CT 3D reconstruction, oblique view demonstrating the iliac AVF (arrow).

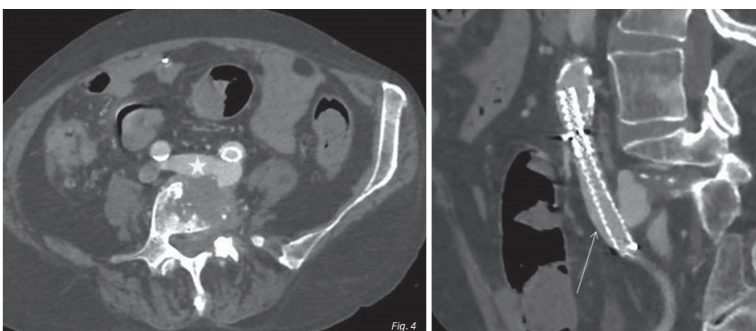


Fig. 4. Post-surgical, axial (left) and sagittal (right) CT, arterial phase, after repair at L4-L5 level. There is absence of venous congestion (asterisk) after stenting of the left common iliac artery (arrow).

with ACF/IAVFs. Open surgery is the treatment of choice for patients with acute symptoms that need emergency repair [7]. In the subacute/chronic phase, endovascular intervention such as stent-graft placement with coil embolisation if AVF is complicated with another vascular lesion (i.e. pseudoaneurysm) or without coil embolisation has become the most efficient therapy. This way a quick and effective treatment is provided preventing from life-threatening complications [9]. Furthermore, it avoids the risk of additional anaesthesia and surgery with the inherent difficulty of controlling the bleeding. In our case, a covered stent-graft repair of the left common iliac artery was performed achieving almost com-

plete occlusion of the fistula and profound improvement of patient's cardiologic-haemodynamic condition and imaging findings at the post-operative follow-up (reduction in the diameter of IVC) (**Fig. 4**). Thus, monitoring of the patient was decided.

Early enhancement of IVC is an imaging sign requiring further analysis. Radiologists should be aware of the pathologic conditions that may exhibit this sign and should be looking for additional imaging findings to reach an accurate diagnosis. **R**

Conflict of interest

The authors declared no conflicts of interest.



KEY WORDS

Arteriovenous fistula/common iliac; Inferior vena cava/early opacification; Computed tomography/diagnosis; Inferior vena cava dilatation

REFERENCES

1. Yeh BM, Kurzman P, Foster E, et al. Clinical relevance of retrograde inferior vena cava or hepatic vein opacification during contrast-enhanced CT. *AJR Am J Roentgenol* 2004; 183(5): 1227-1232.
2. Kandpal H, Sharma R, Gamangatti S, et al. Imaging the inferior vena cava: A road less traveled. *Radiographics* 2008; 28(3): 669-689.
3. Naik KS, Chalmers AG. Pictorial review: The differential diagnosis of early inferior vena caval opacification on dynamic CT. *Clin Radiol* 1997; 52: 504-509.
4. Peter W, Slavomir R, Peter B, et al. Abstract 16305: Cardiac and circulatory adaptation to volume overload: The impact of reduction of high-flow arterio-venous fistula. *Circulation* 2015; 132(suppl 3): A16305.
5. Schmidt R, Bruns C, Walter M, et al. Aorto-caval fistula-an uncommon complication of infrarenal aortic aneurysms. *Thorac Cardiovasc Surg* 1994; 42(4): 208-211.
6. Blumberg SN, Mussa FF, Maldonado TS. Percutaneous fenestrated endovascular aortic graft treatment of aortocaval fistula with aortic pseudoaneurysms secondary to penetrating trauma. *J Vasc Surg* 2017; 66(3): 906-909.
7. Cavalcante LP, Bernardes MV, da Rocha RD, et al. Endovascular treatment of late post-traumatic aortocaval fistula: case report. *J Vasc Bras* 2013; 12(1): 75-80.
8. Szolar DH, Preidler KW, Steiner H, et al. Vascular complications in lumbar disk surgery: Report of four cases. *Neuroradiology* 1996; 38(6): 521-525.
9. Erkut B, Ünlü Y, Kaygin MA, et al. Iatrogenic vascular injury during to lumbar disc surgery. *Acta Neurochirurgica* 2007; 149(5): 511-516.
10. Leech M, Whitehouse MJ, Kontautaitė R, et al. Abdominal aortocaval vascular injury following routine lumbar discectomy. *Case Rep Anesthesiol* 2014; 2014: 895973.



READY - MADE CITATION

Davidhi A, Christoforidis C, Prassopoulos P. Early IVC opacification: One clue, several paths. *Hell J Radiol* 2021; 6(1): 78-82.