

ORIGINAL ARTICLE

Gynecologic Imaging

Knowledge and perception of uterine fibroid among teenage girls with routine pelvic ultrasonographic evaluation of teenagers

Ebbi Donald Robinson¹, Chidinma Wekhe¹, Jeremiah Ebere², Peace Wilson²

¹Department of Radiology Rivers State University Teaching Hospital

²Medical Imaging Technology Rivers State College Of Health Sciences and Technology

SUBMISSION: 17/07/2023 - ACCEPTANCE: 04/09/2023

ABSTRACT

Introduction: Uterine fibroid is the most common benign neoplasm, rare before puberty and in postmenopausal-women. **Methodology:** A descriptive cross-sectional study with free medical outreach of 865 in school teenagers was adopted. Participation was voluntary, however; written consent and ethical approval were obtained prior to commencement. Well-structured pretested questionnaire with the Likert scale multiple questions format of YES, NO, and I Don't know (No opinion); was used. Real time grey scale ultrasonography was done with Sonolite Edge Portable ultrasound machine coupled with 3.5MHz curvilinear probe using standard pelvic ultrasonographic procedure in the presence of a chaperon.

The findings and data retrieved from completed questionnaires were entered into a spreadsheet and analyzed using IBM SPSS version 22.0 statistical software for windows. The results presented using descriptive statistics. **Results:** Participants were aged 13years (n=87, 10.06%), 14years (n=157, 18.15%), 15years (n=199, 23.01%), 16years (n=216, 24.97%) and 17years (23.12%, n=200). Majority of the respondents (81.39%) have not heard of the lesion. The source of information was mainly from family members (55.28%). Spiritual connotation (40.86%) and Smoking (11.83%) were perceived to be associated with the lesion. Normal pelvic ultrasound finding was the most common (82.20%). PID (7.75%), ovarian cyst (1.50%), and



CORRESPONDING
AUTHOR,
GUARANTOR

EBBI DONALD ROBINSON
Senior Lecturer/Consultant Radiologist Department of Radiology Rivers State
University Teaching Hospital
e-mail: drebbirobinson@yahoo.co.uk
ORCID ID: 0000-0002-8509-7854

UTI (7.40%) were also seen. A 13-year-old was having uterine fibroid, while 4 cases teenage pregnancy (0.46%) were seen at ages 16 and 17years. **Conclusion:** There was limited knowledge with associated wrong perception of spiritual connotations concerning the lesion. Uterine fi-

broid was present in a 13-years old teenager; therefore, evaluation of teenagers for uterine fibroid has become imperative, and the inclusion of some gender-based disorders in reproductive health education is recommended.



KEY WORDS

Uterine fibroid, teenage uterine fibroid, teenage pregnancy

Introduction

Uterine fibroid (Uterine leiomyoma) is the most common benign neoplasms in women having a prevalence of approximately 25% (1). The mass arises from the uterine muscle (myometrium) and commonly seen among women of African descent of child bearing age (1). The actual prevalence of fibroid in Nigeria is not known; but it is documented in a hospital based data that the prevalence in Lokoja, Zaria and Ile-Ife are 9.8%, 8.3% and 6.58% in respectively (2). The disease is rare before the age of pubertal but more frequent among nulliparous women and women with cases of infertility (1). It is also rarely seen after menopausal age (1).

The mass varies in sizes within or outside the uterus and could be single or multiple but usually multiple in number (1,3,4). The mass can undergo degenerative changes when prolonged due to the mass outgrowing its blood supply (1,3,4). The degenerative changes can be in form of red/carneous degeneration or calcification, hyaline degeneration (60%), myxoid degeneration (50%), cystic degeneration (5%) as the case may be (1,3,4). The signs and symptoms of uterine fibroid vary based on size, location, and multiplicity (1,3,4). It could present with lower abdominal pain, irregular menstrual bleeding, and palpable abdominal mass (1,3,4). Uterine fibroids can be categorized into submucosal, intramural or subserosal based on the location (1,3,4). The intramural location is the most common type which is seen within the myometrium of the uterus. The intramural type is seconded by the subserosal type while the submucosal is the less common (1,3). Physiologic changes like Pregnancy can co-exist with uterine leiomyoma whereas pathologic conditions like ovarian cyst, endometriosis, and pelvic inflammatory disease can also

co-exist with the mass (1,3).

Ultrasonography, magnetic resonance imaging (MRI), computed tomography (CT), and hysterosalpingography are imaging modalities for diagnostic and post treatment evaluation (3,4), however ultrasonography is the commonest modality used in the evaluation, diagnosis and monitoring treatment of uterine leiomyomas (3). Sonographically, the mass may appear as a well outlined predominately hypoechoic or heterogeneous mass of varying sizes (figure 1 & 2). Myomectomy is the main management option for the lesion, however, hysterectomy, focal endometrial curettage, uterine artery embolization (UAE) and hormone therapy are the other treatment options for the lesion depending on the patients age, parity, fertility status and other comorbidities (5, 6).

The teenage age being the pre-adult age (pre-adulthood) between 13 and 17years (7). During this age (teenagers) the persons are learning to define their priorities, their own values, goals and self-realization (7). At this age they are beginning to gain a sense of belonging to their immediate environment, community and the world around them (7). At this point they tend to develop their own unique identity. With this evolution around and within them, they tend to have lots of questions of which most persons may not have answers to. Being a time of great change, confusion and stress, they are sometimes construed to believing that which is untrue and accepting issues as they perceive them (7). They become very vulnerable to circumstances around them especially health related issues. Uterine fibroids usually develop during childbearing age being from the period of puberty to before menopause (3). Thus, this disease is rare in children and girls before the age of puberty (1,3).

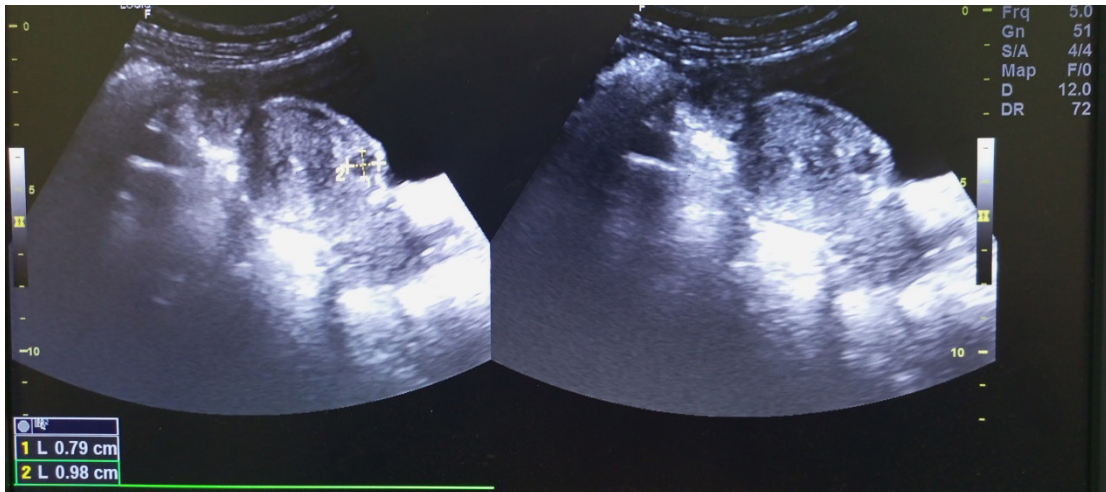


Figure 1 Static grey scale sonograms of a subserosal heterogeneous but predominately hypoechoic mass in the anterior aspect of the uterus measuring approximately 9.8mmX7.9mm.

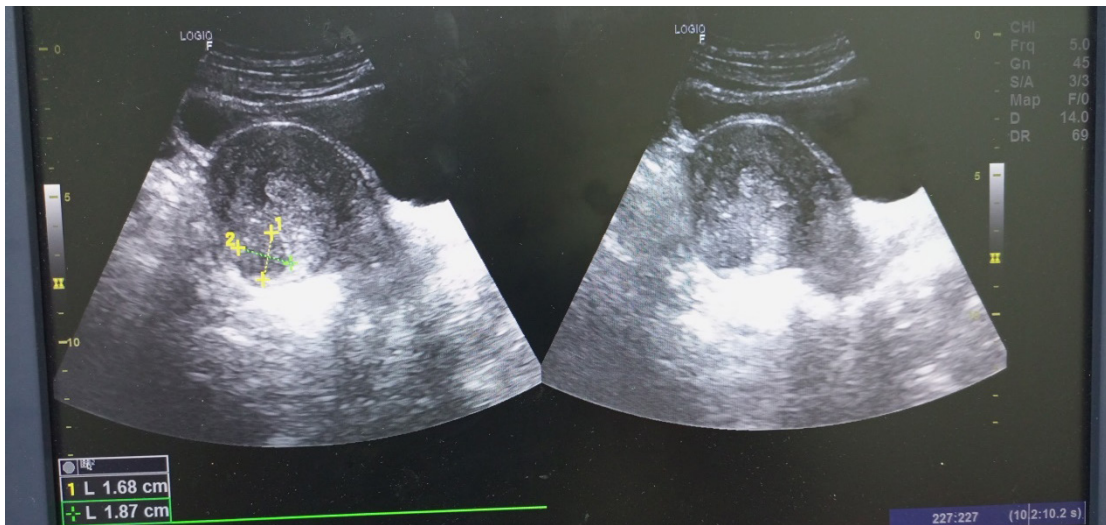


Figure 2 Static grey scale sonograms of a subserosal heterogeneous mass in the posterior aspect of the uterus.

Although it is quite rare among women below 20 years of age, but there is a reported case of the disease (uterine fibroid) in a 16-year-old teenager (8). According to the report by Murphy *et al* (8) the 16-year-old female teenager presented with severe anemia and abnormal uterine bleeding. A symptomatic uterine fibroid was also seen in a 15-year-old girl necessitating laparoscopic myomectomy (9). Because of the epidemiology data of the effect of uterine fibroid on black women, its association with nulliparity and the prevailing misconception it has become imperative for proper education of women including the teenage girl.

Notwithstanding, the few documented cases of uter-

ine fibroid among adolescence, there is still paucity of data concerning the lesion among teenagers in our environment. It is also important to ascertain the knowledge and perception of uterine fibroid among the teenage girls. The findings from the study will not only necessitate the early orientation and education of the teenage girl concerning the disease but will also enable clinicians in paying close attention to teenage girls when evaluating them for pelvic related symptoms.

Methodology

A cross-sectional descriptive study design was adopted for the study. The study was carried out over

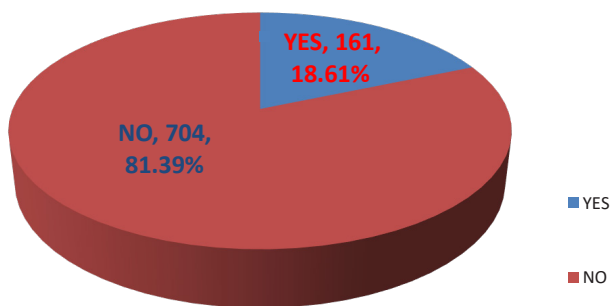


Figure 3. Participants who have heard of Uterine fibroid

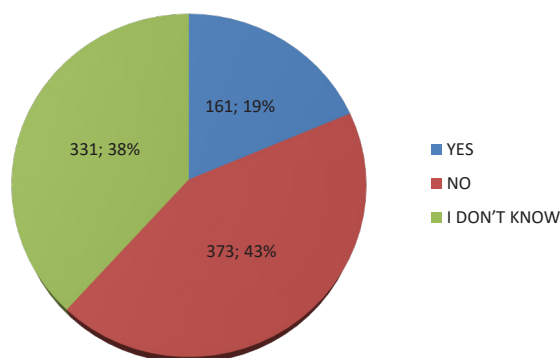


Figure 4. Knowledge of fibroid

6 months among 865 young secondary school girls in Port Harcourt City Local Government Area and teenage girls who also voluntarily participated during the free medical and surgical care programme organized by Opu-Alabo Foundation at Buguma-City in Asari-Toru Local Government Area.

A well-structured questionnaire made up of three sections was used for the study to collect the required information from the respondents. The first segment consists of information concerning the respondent's sociodemographic variables such as age, school cadre and menarche. The second segment involves background knowledge of uterine fibroid while the third segment assesses the respondent's perception about the disease. The questionnaire was pretested to ascertain its validity in quality and content. The Likert scale multiple questions of three options pattern such as YES, NO, and I Don't know (No opinion); were used for the questionnaires.

The purpose of the study as contained in the ques-

tionnaire was disclosed clearly in understandable terms to the respondents before obtaining informed consent. The questionnaires were distributed to young school-girls/ teenage girls after appropriate permission from the school management and consents. The completed questionnaires were retrieved from the respondents immediately after completion. Both interview based and self-administered models were employed in the administration of the questionnaires. Out of the 1375 copies of questionnaires distributed 856 copies were retrieved.

The author(s) ensured that participation was absolutely voluntary and high level of confidentiality maintained concerning the information provided by the respondents. After obtaining informed consent, questionnaire administered and retrieved, the respondents were then evaluated for transabdominal pelvic ultrasound scan using Sonolite Edge Portable Ultrasound machine coupled with 3.5MHz curvilinear probe.

The transabdominal pelvic ultrasound scan was per-

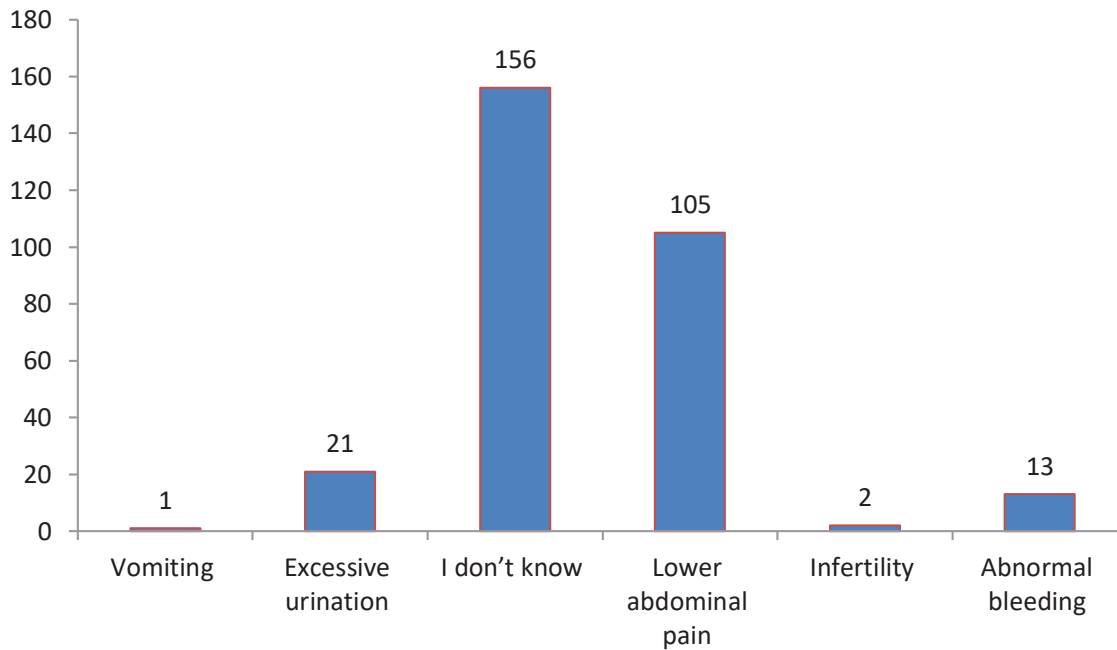


Figure 5 Knowledge of the sign(s) and symptom(s) of uterine fibroid

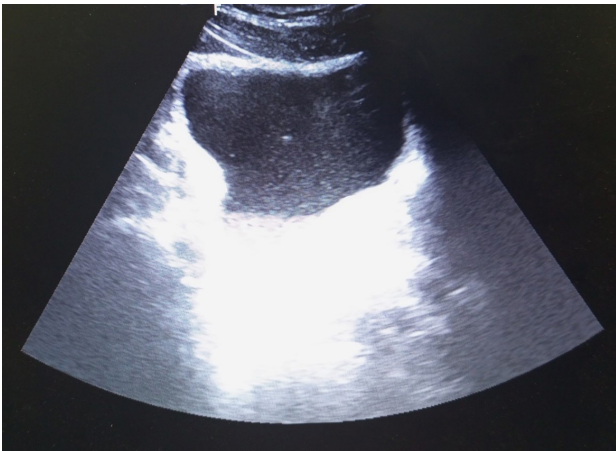


Figure 6. Static grey scale sonogram showing the urinary bladder s containing multiple echogenic specks within the urine.

formed with the prior intake of approximately 500mls of water to attain adequate bladder distension. The bladder distension is used as an acoustic window for proper visualization of the uterus and the adnexa. The investigation was conducted with the patient lying supine on the couch exposing the lower abdomen and pelvis (from the umbilicus to the symphysis pubis) in the presence of a chaperon. The ultrasound acoustic gel was applied to the suprapubic region before plac-

ing the probe to evaluate the pelvis. The acoustic gel functions to obliterate air interface between the skin and the transducer and the patient was scanned in the longitudinally and transverse planes.

After the examination, the sonographic findings and data retrieved from the questionnaires were collated and entered into a spreadsheet, using IBM SPSS version 22.0 statistical software for windows, and analyzed with descriptive statistics. The results were presented as percentages, frequency, tables, charts and figures. Institutional based ethical approval was obtained from the Health Research and Ethics Committee prior to the commencement of the study and written consent obtained from each participant before involvement in the study.

Results

Eight hundred and sixty-five respondents participated in the study and participants were aged 13years (n=87, 10.06%), 14years (n=157, 18.15%), 15years (23.01%, n=199), 16years (n=216, 24.97%) and 17years (23.12%, n=200) as shown on table 1. Table 2 shows the educational Class/cadre of the participant which illustrates that majority of the participants were in SS 3

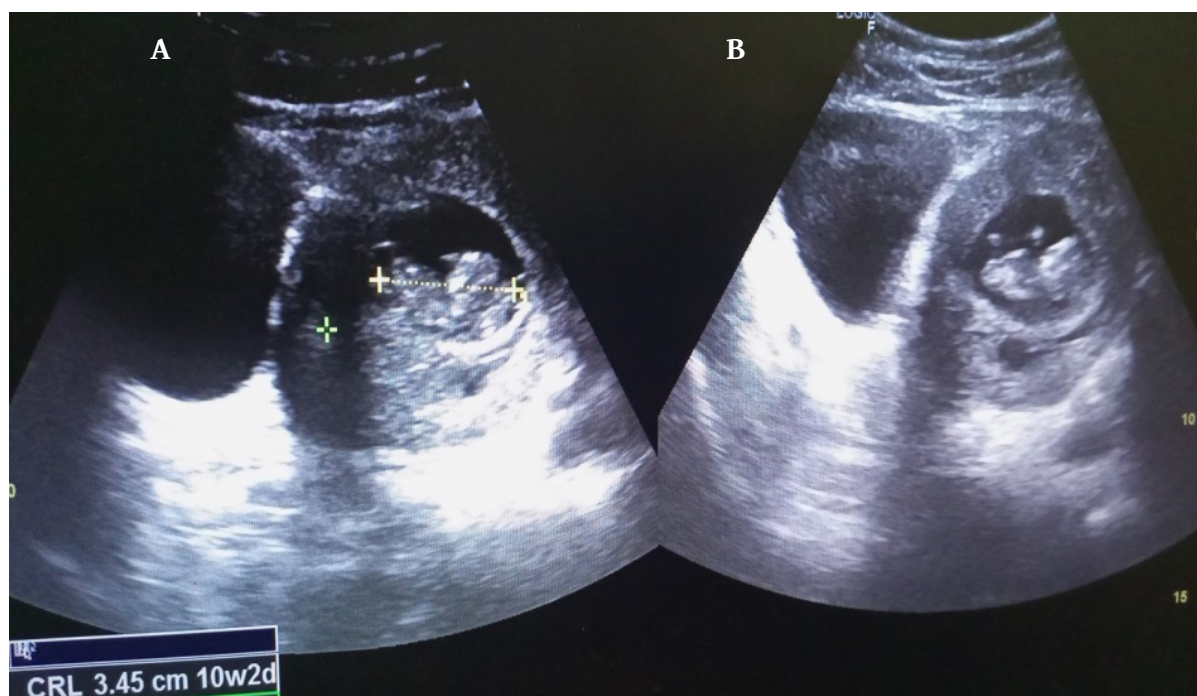


Figure 7. Static grey scale sonogram showing a gravid uterus harboring a singleton fetus in transverse position in a 16 year old teenager (A) the CRL measurement of the fetus (B)

(n=292, 33.76%) while 7.17% (n=62) were in Basic 9 and 14.91% (n=129) of the respondents have completed secondary school (Post-Secondary).

Concerning the age of menarche of respondents, 4.39% (n=38) have not had menarche while 95.61% (n=827) have had menarche and 4 participants ages 14 years and a respondent's aged 15 years have not had menarche of which the latter is indicative of delayed menarche (table 3). According to figure 3 majority (81.39%) of the respondents have not heard of uterine fibroid whereas out of the number of respondents that have heard of the lesion only 1.24% have had some form of formal teaching, education or counseling on fibroid (table 4).

Table 5 illustrates the knowledge of uterine fibroid according to age distribution. The table (table 5) shows that the highest number of respondents who have heard of the lesion are those of 17 years (n= 69) and knowledge of the disease increased with increase in age. Figure 4 illustrates the knowledge of fibroid among the respondents. According to figure 4, 19% (n=161), 43% (n=373) and 38% (n=331) have knowledge (YES), no knowledge (NO) and don't know anything about it respectively.

Table 6 illustrates that out of the 166 respondents

that have knowledge concerning the disease only 1.24% (n=2) have in-depth understanding of the part of the body affected by the lesion whereas 75.16% (n=121) of them do not know the body region affected.

Majority of the respondent who had knowledge of the lesion heard it from family members (n=89, 55.28%), NGOs (n=27, 16.77%) and from the social media (n=27, 16.77%) as shown on table 7. As shown in table 8, spiritual problem was perceived to be associate with the lesion by 40.86% (n=76), while 22.04% (n=41) thinks that it is caused by STD/STI. Whereas 11.83% (n=22) of the respondents also opined that the lesion is associated with Smoking.

Majority of the respondents do not know the symptoms and signs of uterine fibroid (n= 156), however to the best of their knowledge infertility (n=2), abnormal vaginal bleeding (n=13) and excessive urination (n=21) among others were the symptoms of the lesion (figure 5).

The outcome of the pelvic ultrasonography was shown on table 9 which revealed a normal finding in majority of the respondents (n=711, 82.20%). However, out of the abnormal outcomes PID was the most com-

Table 1. Age distribution of respondents

Age (years)	No. of respondents	Percentage
12	6	0.69%
13	87	10.06%
14	157	18.15%
15	199	23.01%
16	216	24.97%
17	200	23.12%
Total	865	100

Table 2. Educational Class/cadre distribution of participant

Variables	No. of Respondents	Percentage
Basic 7	1	0.12%
Basic 8	5	0.58%
Basic 9	62	7.17%
SS 1	122	14.10%
SS 2	264	30.52%
SS 3	292	33.76%
Post-Secondary	129	14.91%
Total	865	100

Senior Secondary (SS)

mon finding accounting for 7.75% (n=67). The other findings include Uterine Leiomyoma (n=5, 0.58%), and Ovarian Cyst (n=13, 1.50%). According to table 9, 7.40% (n=64) was diagnosed of UTI sonographically seen as echogenic speaks in the urine (figure 6). One case of uterine fibroid was seen at age 13years, 15years and 16years while 17years of age recorded two cases (Table 9). Table 9 also demonstrates 4 cases (0.46%) of teenage pregnancy at ages 16 and 17years. The pregnant uterus is seen ultrasonographically as a gravid uterus harboring a singleton fetus in transverse position in one of the 16 year old teenagers (figure 7).

Discussion

The study was to evaluate the knowledge and perception of uterine fibroid among teenage girls and the

spectrum of pelvic ultrasonographic findings following routine pelvic ultrasonography. Eight hundred and sixty-five respondents participated in the study and majority of the respondents were aged 16years while the least were aged 12years. Out of the 865 participants drawn from secondary schools and the free medical care program which included a routine pelvic ultrasonography showed that majority of the participants are within the senior secondary carder. The age of respondents and the educational carder obtained from the study may be due to increasing maturity, willingness and understanding being at the upper limit of the teenage age group.

Most of the respondents have had menarche and the earliest menarche was recorded to be at the age of 12 years, however, delayed menarche was seen at the age of 15 year. Majority of the respondents have not heard

Age	No menarche		Menarche		Total
	Frequency	Percentage	Frequency	Percentage	
12years	2	0.23%	4	0.46%	6
13	31	3.58%	56	6.47%	87
14	4	0.46%	153	18.50%	157
15	1	0.12%	198	23.94%	199
16	-	-	216	26.12%	216
17	-	-	200	24.18%	200
Total	38	4.39%	827	95.61%	865

Variables	No. of Respondents	Percentage
Yes	2	1.24%
No	96	59.63%
I don't know	62	38.51%
Total	161	100%

of uterine fibroid. The knowledge of uterine fibroid following to age distribution revealed that the highest numbers of respondents who have heard of the lesion are those of 17 years with its knowledge increasing with increase in age.

According to Adegbesan-Omilabu et al (10) to evaluate “the knowledge of, perception of, and attitude towards uterine fibroids among women with Fibroids in Lagos, Nigeria” showed that majority (98.6%) of the participants know about uterine fibroids. The finding from their study (10) was completely converse to the findings from the index study where majority of the respondents have not heard about the lesion. The reason can be attributed to the fact that the index study group were teenagers while the study by Adegbesan-Omilabu, et al (10) was among adults was the least age group was 20–24years accounting for only 1% of their study population.

Out of the 166 respondents that have knowledge concerning the lesion only 1.24% has some understanding of the part of the body affected by the lesion while ma-

majority of them do not know. Only 2 of the respondents have had some form of formal teaching, education or counseling on uterine fibroid while the majority of the respondents has not received any form of formal education concerning uterine fibroid which may have contributed to the lack of knowledge about uterine fibroid. This may also have contributed to limited knowledge concerning the disease.

The present study showed that majority of the information concerning uterine fibroid was received from family members (55.28%), followed by NGO (16.77%) and social media (16.77%). It is therefore opined that respondents may have heard of the disease from family members or relatives who may have had the lesion and secondly from NGO who may have visited their institution to give female gender based health enlightenment programs and counseling. The sources of information was similar to that documented by Adegbesan-Omilabu, et al, (10) however the main source of information in their study (10) was the radio followed by parents/relatives, and health workers.

Age (years)	YES	NO	I don't know	Total
12	1	3	2	6
13	3	57	27	87
14	14	65	78	157
15	28	72	99	199
16	46	78	92	216
17	69	98	33	200
Total	161	373	331	865

Variables	No. of Respondents	Percentage
Yes	2	1.24
No	121	75.16%
I don't know	38	23.60%
Total	161	100%

Variables	No. of Respondents	Percentage
Social Media	27	16.77%
Radio	2	1.24%
TV	2	1.24%
Class Room	2	1.24%
Family	89	55.28%
Friends	12	7.45%
NGO	27	16.77%
Total	161	100.00%

Non-governmental organization (NGO)

Spiritual connotation was perceived to be associated with the lesion by as much as 40.86% of those who have heard of the disease. This finding was in consonance with that documented by Adegbesan-Omilabu, et al, (10) where up to 69.0% of the respondents believed

that uterine fibroid has spiritual affiliation. It is opined that the spiritual connotation may have some negative impact on the reasoning of the respondents when diagnosed of the mass wherein patients will be seeking native therapy instead of a proper health seeking be-

Table 8: Perception concerning the uterine fibroid

Variables	No. of Respondents	Percentage
Is a Spiritual problem	76	40.86%
Taking of excess sugar	21	11.29%
Caused by STD/STI	41	22.04%
Alcohol intake	21	11.29%
Smoking	22	11.83%
Total	186	100%

Sexually transmitted diseases / infections (STD/STI)

Table 9: Outcome of pelvic ultrasonography

Variables	12	13	14	15	16	17	Frequency	Percentage
Normal	5	83	108	179	162	135	711	82.20%
PID	-	-	4	9	23	31	67	7.75%
Uterine Leiomyoma	-	1	-	1	1	2	5	0.58%
Ovarian Cyst	-	-	-	2	4	7	13	1.50%
UTI	1	3	5	8	25	23	65	7.52%
Pregnancy	-	-	-	-	2	2	4	0.46%
Total	6	87	157	199	216	200	865	100%

Pelvic Inflammatory Disease (PID),

haviour for the treatment for fibroid.

The lack of knowledge and perception of respondents also revealed that some of the respondents thinks it is caused by STD/STI and Smoking. Although the cause of the mass is unknown, STI and smoking are not directly associated with the etiology and pathogenesis of uterine fibroid. Majority of the respondents do not know the symptoms and signs of uterine fibroid and to the best of their knowledge infertility, abnormal vaginal bleeding and excessive urination were the symptoms of the lesion.

The routine pelvic ultrasonography outcome showed that maturity of the teenager had normal pelvic finding (82.20%). However, out of the abnormal outcomes includes PID been the most common finding (7.75%), Uterine Leiomyoma (0.58%), Ovarian Cyst (1.50%), and

UTI ((7.40%).

One case of uterine fibroid was seen at age 13years, 15years and 16years while 17years of age recorded two cases. Although available literature have documented that uterine fibroids are rear at the teenage age, pockets of teenage uterine leiomyoma is now seen. Similar finding of fibroid was documented in a case report by Morita et al (11) where uterine leiomyoma was seen in 13year old teenager. Teenage uterine fibroids were seen in a 16 and 19-year old as recorded by Zigman et al [5] and Gong et al [12] respectively. There were also 4 cases of teenage pregnancy at ages 16years and 17years.

Limitations were encountered during the Study which includes certification of the date of births of the respondents as there was neither a birth registry nor original birth certificate to certify the actual date of birth. A

few had their parents certify the date of birth whereas majority of the respondent's testimonials of the date of birth was used. Inadvertently some may be above or below the specified age. There were also institutional and personal challenges regarding the study because of the gender based nature of the study. Some of the girls were also very reluctant in answering the questions and some completely not informed about the subject matter.

Conclusion

The study of the knowledge and perception among teenage girls revealed that there is server lack of knowledge with associated poor perception and connotations concerning the lesion. As against the backdrop of available data concerning less prevalence of the lesion among teenagers, a 13 year old teen was seen with the lesion. It has become imperative not to ignore the evaluation of teenage girls for uterine fibroid. More emphasis should be made on how to educate and create awareness of uterine fibroids. TVs and Radio programs should

be recommended and also seminars should be made to make sure a lot of these girls get to know more about them.

The poor knowledge and perception of uterine fibroids of the school girls as observed in this research are problems seen to be based on lack of awareness or improper awareness of uterine fibroid to the young, teenage girls. The study recommends more gender-based education of the girl child as well as inclusion of some of the gender based disorder in reproductive health education. **R**

Conflict of interest

There is no conflict of interest

Acknowledgement

The authors gratefully acknowledge Opu-Alabo foundation for sponsoring the free medical programme in Buguma General Hospital in Asari-Toru Local Government Area of Rivers State, Nigeria

REFERENCES

1. Farooq S, Leong Y, Knipe H, et al. Uterine leiomyoma. Reference article, Radiopaedia.org (Accessed on 13 Mar 2023) <https://doi.org/10.53347/rID-10915>
2. Fasubaa OB, Sowemimo OO, Ayegbusi OE, Abdur-Rahim ZF, Idowu BS, Ayobami O, Babalola OE, Akindojutimi AJ.: Contributions of uterine fibroids to infertility at Ile-Ife, South-Western Nigeria. *Trop J Obstet Gynaecol* 2018; 35:266-70
3. Ijeruh OY, Robinson ED, Alaziha N, Lawson AM and Wekhe C. Radiologic Pattern of Uterine Leiomyoma among Rural Women Undergoing Routine Pelvic Ultrasonography in South-South Nigeria. *African Journal of Health Sciences* Volume 34, Issue No. 2, March – April 2021
4. Wilde, S., & Scott-Barrett, S.: Radiological appearances of uterine fibroids. *The Indian journal of radiology & imaging*, 2009; 19(3), 222-231. <https://doi.org/10.4103/0971-3026.54887>
5. Zigman JS, Brotherton J, Truong C, Yazdany T. Surgical Planning and Counseling in Adolescence: A Case Report of a 16-Year-Old with an Aborting Pelvic Mass. *Gynecol Minim Invasive Ther*. 2018 Oct-Dec;7(4):175-177. doi: 10.4103/GMIT.GMIT_19_18. Epub 2018 Sep 26. PMID: 30306038; PMCID: PMC6172877.)
6. Okezie O, Ezegwui HU. : Management of uterine fibroids in Enugu, Nigeria. *J Obstet Gynaecol* 2006; 26:363-5.
7. A Child's Age and Stage of Development Make a Difference. <https://www.justice.gc.ca/eng/rp-pr/fl-lf/divorce/age/age2c.html>. Date modified: 2022-12-21
8. Murphy CA, Zarudskaya O, Kakish C, Zoorob D, Seo-Patel S. Uterine Fibroid in a 16-Year-Old Adolescent Managed with a Fertility-Sparing Approach: A Case Report and Review of the Literature. *J Pediatr Adolesc Gynecol*. 2021 Jun;34(3):427-431. doi: 10.1016/j.jpag.2020.12.016. Epub 2021 Feb 13. PMID: 33359317.

- 9 Salehi PP, Tyson N. Laparoscopic Myomectomy of a Symptomatic Uterine Leiomyoma in a 15-Year-Old Adolescent. *J Pediatr Adolesc Gynecol.* 2016 Dec;29(6):e87-e90. doi: 10.1016/j.jpag.2016.05.007. Epub 2016 Jun 2. PMID: 27262836.
- 10 . Adegbesan-Omilabu MA, Okunade KS, Gbadegesin A. Knowledge of, Perception of, and Attitude towards Uterine Fibroids among Women with Fibroids in Lagos, Nigeria. *Scientifica (Cairo).* 2014;2014:809536. doi: 10.1155/2014/809536. Epub 2014 Mar 13. PMID: 24757580; PMCID: PMC3976850.
11. Morita N, Tanaka T, Hashida S, Tsunetoh S, Taniguchi K, Komura K, Ohmichi M. Uterine leiomyoma in a 13-year-old adolescent successfully treated with laparoscopic myomectomy: A case report. *Medicine (Baltimore).* 2019 Dec;98(49):e18301. doi: 10.1097/MD.00000000000018301. PMID: 31804377; PMCID: PMC6919386
12. Gong YY, George V, Appleton J, Guan X, Adeyemi-Fowode O. Single Incision Laparoscopic Surgery for Leiomyoma in the Adolescent Patient: A Case Report. *J Pediatr Adolesc Gynecol.* 2021 Aug;34(4):573-575. doi: 10.1016/j.jpag.2021.02.103. Epub 2021 Mar 3. PMID: 33675982..)



READY - MADE
CITATION

Ebbi Donald Robinson, Chidinma Wekhe, Jeremiah Ebere, Peace Wilson. Knowledge and perception of uterine fibroid among teenage girls with routine pelvic ultrasonographic evaluation of teenagers. *Hell J Radiol* 2023; 8(3): 24-35.