

Impact of MSCT in pre-operative assessment of temporal bone in pre-lingual and post-lingual SNHL prior to cochlear implantation

Amal I A. Othman¹, Fatma S. Mohammed¹, Mostafa S A. Elghobashy², Ali H. Ali¹

¹Radiodiagnosis Department, Hospitals of Ain Shams University, Cairo, Egypt.

²Military Medical Academy, Cairo, Egypt.

SUBMISSION: 10/04/23 - ACCEPTANCE: 06/12/2023

ABSTRACT

Aim: Multi-slice CT (MSCT) is considered a crucial diagnostic tool in the detection of various etiologies of sensorineural hearing loss (SNHL) which demand different therapeutic methods of which cochlear implantation is considered the surgical procedure of choice in the management of profound SNHL. MSCT scan of the petrous bone plays an important role in the preoperative assessment and selection of cases prior to cochlear implantation.

Methods: This study had a total number of 30 patients referred from the E.N.T. department to the department of radiodiagnosis. MSCT was done for evaluation of

the cochlear condition before cochlear implantation surgery. MSCT was used to reveal the different inner ear anatomical variants and to orient and modulate the surgical techniques. It was also used to determine the causes of SNHL in pre-lingual (patients who never speak before) and post-lingual (after speech acquisition) patients.

Results: Only 25 out of 30 patients were good candidates for cochlear implantation surgery according to radiological data, the remaining five cases were not submitted to surgery because they had contraindications, and one case was diagnosed as Michele anomaly (which



CORRESPONDING
AUTHOR,
GUARANTOR

Dr. Krishna Teja Nerella, MD
Assistant Professor, Department of Interventional Radiology,
Dr. D.Y. Patil Medical College, Hospital and Research Centre,
Pune, India. Email: krishna.teja666@gmail.com

is an absolute contraindication), one case diagnosed as Labyrinthitis ossificans (which may affect the insertion of the cochlear array), one case diagnosed as bilateral longitudinal fractures (this case has been postponed for fear of cochlear nerve affection) & two cases were diagnosed as normal studies on imaging and assumed clin-

ically as post meningitic labyrinthitis and they are on waiting list due to correlation of their relatively larger age and availability of cochlear implant devices

Conclusions: MSCT is considered the modality of choice in the assessment of patients with SNHL preoperatively.



KEY WORDS

CT /pre-operative /cochlear implantation/ temporal bone.

Background:

The cochlear implant device is considered a very advanced smart machine that is embedded surgically within the cochlea of patients who complained of profound sensorineural hearing loss bilaterally and have not gained benefit from the usual sound amplification hearing aids [1].

The cochlear implantation procedure is the only United States Food and Drug organization-accepted surgical intervention as management for children complaining of SNHL bilaterally. It gives the patients many auditory benefits which range from simple sound detection to a high level of word determination and understanding [2].

Candidates for cochlear implantation should have a checklist of preoperative assessment including clinical, speech therapeutics, psychological, and social criteria. At this stage, diagnostic imaging of the cochlear area is crucial in detecting the possible etiology of hearing loss, locating signs that may contraindicate surgical procedure, choosing the proper ear to be implanted, in good assessment of the morphology for surgery, and - within limits - in predicting possible complications [3].

At present, there is a wide use of multi-slice CT machines in imaging of the petrous temporal bone which provide better imaging of that complex part. The reformatted multiplanar 3D images from traditional cross-sectional conventional CT data have been used to delineate the petrous bone morphology and pathology [4].

MSCT plays a vital role in the assessment and management of various etiologies of hearing loss which require many therapeutic modalities including cochlear implantation. Generally, most etiologies of hearing dis-

abilities including for example, congenital inner ears anomalies such as the absent or malformed cochlea, dilated endolymphatic sac, narrow internal auditory canal, and maybe cerebello-pontine angle tumors, are best detected by CT scan of the petrous bone using a bone algorithm and windowing modalities [5].

During cochlear implantation surgery, there are sequential main surgical steps that are influenced by anatomical variants between different patients, preoperative petrous bone MSCT scan can be of great benefit in the prediction of any possible obstacles that may be problematic during the cortical mastoidectomy, facial recess access and round window approach in cochlear implantation procedure [4].

The 3D volume rendered CT data can help in understanding the temporal bone morphology. These images can be rotated in space and processed in different planes allowing assessment of morphologic features of every single structure including the small ossicles of the middle ear and other inner ear structures [6].

Early diagnosis with accurate imaging is highly important for a management protocol. It influences the proper selection of candidates and decides who will benefit more from hearing aid implants or corrective surgical procedures. The advantage of a multi-slice CT scan of petrous bone is expected to play a major role in preoperative assessment [7].

Aim of Work:

Evaluation of the multi-slice CT role in the preoperative assessment of pre-lingual and post-lingual cochlear implant candidates and selection of the appropriate candidates for cochlear implantation procedure.

Methods:

This retrospective study included a total number of 30 patients (13 males and 17 females) who complained of severe sensorineural hearing loss bilaterally. The patient's ages ranged from 1 to 45 years and 8.05 years was the mean age of the study group. All patients were referred to the Radiodiagnosis department from the ENT Department of El-Galaa Military Hospital. Imaging was done for preoperative evaluation in the radiology department.

CT was performed for delineation of the cochlear & inner ear structural morphological condition before the implantation procedure. The CT study helps in the assessment of various inner ear morphological anatomy which may affect and change the surgical strategy.

Ethical Approval:

An approval of the study was obtained from Ain Shams University Academic and Ethical Committee (FMASU MD 118/2021), Informed consent from patients / their parents to participate in this study was obtained according to the ethical approval. This work has been carried out in accordance with the Federal Wide Assurance No. FWA 000017585.

Inclusion criteria:

Patients with different age groups were diagnosed with pre-lingual and post-lingual (congenital or acquired) sensorineural hearing loss. No gender predilection.

Patient preparation:

A detailed history was taken with special concern on the complaints of the patients and their present illness. A full general examination and local otological examination were done. Detailed procedural explanation to the relatives/patients was performed. Informed consent from the relatives/patients was obtained.

Technique & parameters of CT imaging:

The patients were informed to be in a supine position with their head first then axial images were obtained from the top of the petrous bone apex to the inferior tip of the mastoid bone. Coronal reformatted images were obtained from the anterior margin of the petrous bone apex to the posterior margin of the mastoid bone. All

the images were assessed and reviewed with a high-resolution bone algorithm and a small field of view for separate processing of the right and left ears. Multiplanar reformatted images (in addition to axial images) were used for accurate measurements of various bony canals in the inner ear structures.

The study was performed with the following parameters: a 15-cm field of view, 0.75-mm section thickness, 200 mAs, 120 kVp, and a matrix size of 512* 512. The initial gathered data were then reconstructed at 0.1-mm intervals. The data acquisition was collected as a volume, starting from the jugular foramen up to the superior margin of the petrous pyramid. The usual preferred CT plane to display the petrous bone was the axial plane parallel to the infra-orbital-metal line.

Post-processing:

This includes coronal and sagittal planes 2D reformatted images, and images with multiplanar reformatted techniques were created. Images in the sagittal oblique plane were taken parallel to the short and long axes of the cochlear turns, cochlear aperture, and modiolus.

Image interpretation:

The most important pre-surgical implantation CT checklist included: cochlear presence, morphology and patency, vestibular and SCC morphological anatomy, internal auditory canal (IAC), vestibular and cochlear aqueduct, patency of the middle ear pathway, pneumatization of the mastoid air cells and position of jugular bulb [8].

Image analysis:

Each case was assessed for different abnormalities requiring cochlear implantation, congenital versus acquired lesions, and whether cochlear implantation would be beneficial for the patient or not.

Results:

This study included a total number of 30 patients with bilateral severe to profound sensorineural hearing loss (SNHL). The study was performed on 13 males (43.3%) and 17 females (56.6%). The age of the total sample ranged from one year to 45 years, mean age of 8.05 years.

A wide range of age groups was included in the study

Table 1: Distribution of patients according to age and sex group.

Age group	No. of Patients	Males	Females
1-3	19 (63.3%)	9	10
4-8	6 (20%)	2	4
>8	5 (16.7%)	2	3
Total	30 (100%)	13	17

Table 2: Distribution of patients according to the onset of hearing loss.

Onset	No. of patients	%
Pre-lingual	22	73.3
Post-lingual	8	26.7

Table 3: Frequency of etiological factors of SNHL among the study group.

Aetiology	Total of SNHL	Frequency
Congenital (prelingual)	8	26.7%
Acquired (Inflammatory) (pre/ post-lingual)	21	70%
Acquired (Traumatic) (post-lingual)	1	3.3%
Total	30	100%

Table 4: Distribution of the inner ear MSCT findings.

MDCT findings	No. of patients	%
Normal (pre/post-lingual)	20	66.7
Congenital inner ear malformations (prelingual)	8	26.7
• Absent inner ear structures		
• Incomplete Partition type II (IP II)	1	
• Vestibular dilatation	2	
• Vestibular aqueduct Syndrome	1	
	4	
Post meningitic calcification (post lingual)	1	3.33
Traumatic (post lingual)	1	3.33
Total	30	100

Table 5: Distribution of the congenital anomalies in different ear compartments.

Site of congenital anomalies (prelingual patients)	No of patients	%
Inner ear alone	7	23.3%
Mixed external, middle & inner ear	1	3.3%
Mixed external and middle with normal inner ear	1	3.3%
total	9	30%

from both genders. The most common age group is from 1-3 years representing 63.3% of cases. Females were more affected than males representing 56.6% of the cases (table 1).

Sensory neural hearing loss could be subdivided according to the onset of hearing loss, into two main categories: pre-lingual (deafness before patients begin to speak), and post-lingual (deafness after the acquisition of speech), with the pre-lingual cases being more common, representing 73.3% of cases (Table 2).

Various causes of SNHL could be subdivided into two main groups: congenital (exclusively prelingual) versus acquired (pre or post-lingual) aetiologies. The acquired aetiologies were subsequently divided into inflammatory & traumatic causes as noted in (Table 3). The most common cause for SNHL was acquired inflammatory causes, found in 21 patients representing 70 % of total number of cases.

The congenital aetiologies (prelingual patients) of SNHL contain variable entities of inner ear structural anomalies, as shown in (table 4). Most patients had normal MSCT studies of the inner ear (20 out of 30 patients). Congenital abnormalities of the inner ear were detected in only 8 cases representing 26.7% of cases. Many of the patients with congenital inner ear abnormalities have other congenital anomalies in the external or middle ear or both.

The diversity of congenital inner ear anomalies could range between solitary or mixed inner ear anomalies or associated inner and other external or middle ear anomalies in the same case, as shown in (table 5). Most of the cases show solitary inner ear involvement. One case shows mixed external, middle, and inner anomalies & another one shows mixed external and middle ear anomalies, with a normal inner ear.

Only 25 of 30 patients were the best candidates for cochlear implantation procedure and they had under-

gone the surgical procedure successfully, while the other five cases were not good candidates for cochlear implantation. These cases involve a case diagnosed as Michele anomaly (bilateral absent inner ear structures) which is considered a contraindication for cochlear implantation). Another one was diagnosed as labyrinthitis ossificans which involves deposition of calcium within the labyrinthine canal which may affect insertion of the wire during cochlear implantation operation. The third case was diagnosed as bilateral longitudinal fractures and was postponed for fear of affection of the cochlear nerve which, if true, means that the operation is non-useful. The last two cases were diagnosed as normal studies on imaging and assumed clinically as post-meningitic labyrinthitis and they are on the waiting list due to the correlation of their relatively larger age and the non-availability of cochlear implant devices.

In patients with other associated congenital anomalies in the external or middle ear, cochlear implantation was done in the other ear to raise the % of success. In patients with inner ear anomalies, the severity of malformation is inversely correlated with post-implantation speech perception performance. Children with dilated vestibular aqueduct and incomplete Partition type-II tend to perform very well, whereas those with common cavity or hypoplastic anomalies tend to perform poorer speech performance due to decreased neural stimulation.

Illustrative cases:

Case 1:

A female patient two years old complained of prelingual profound Sensorineural hearing loss. MSCT showed within average cochlear bilateral basal turns with a cystic malformed apex on each side, vestibular enlargement, dilated vestibular aqueduct reaching 3.65 mm in diameter, containing a dilated endolymphatic sac, and

normal semi-circular canals (Fig.1), findings suggestive of Mondini abnormality (Incomplete Partition type II) (IP II). According to CT findings, this case was a good candidate for cochlear implantation, and surgery was done successfully.

CT findings are suggestive of Mondini abnormality (IP II).

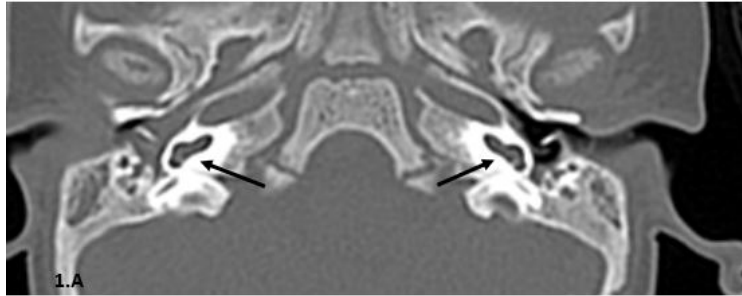


Figure 1. A: Axial CT bone window revealed bilateral normal basal cochlear turns (black arrows).

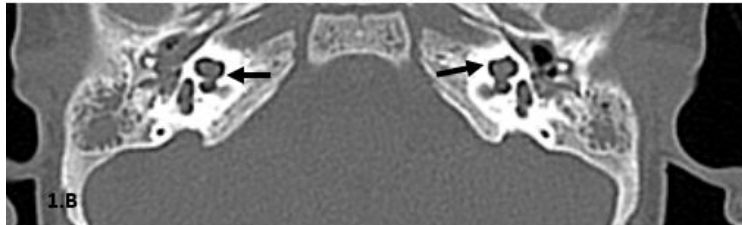


Figure 1. B: Axial CT bone window revealed bilateral cochlear cystic malformed apex (black arrows).

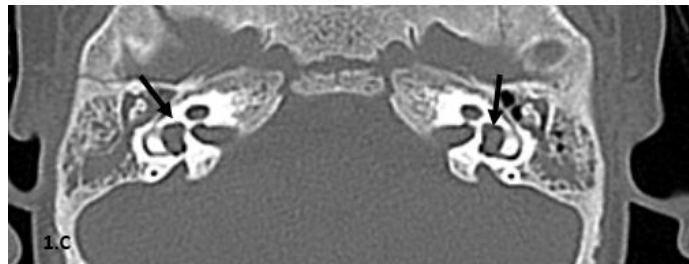


Figure 1. C: Axial CT bone window revealed bilaterally enlarged vestibules (black arrows).

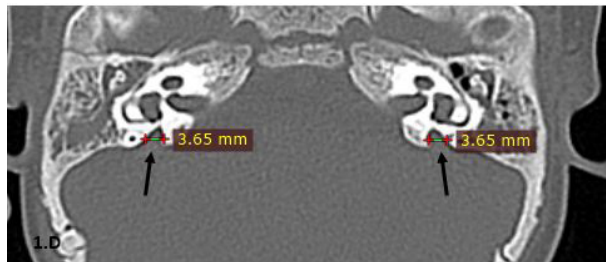


Figure 1.D: Axial CT bone window revealed bilateral dilated vestibular aqueducts (black arrows). Normal diameter less than 1.5 mm.

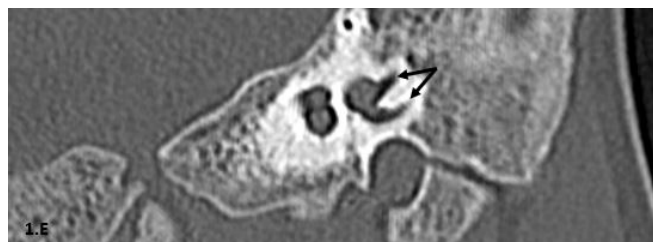


Figure 1.E: left coronal oblique CT bone window revealed average semicircular canals (black arrows).

Case 2:

A male patient 2.2 years old diagnosed with prelingual profound Sensorineural hearing loss. MSCT showed isolated bilateral vestibular aqueduct dilatation, with normal inner ear structures (Fig.2). According to CT findings, this case was a good candidate for cochlear implantation, and surgery was done successfully.

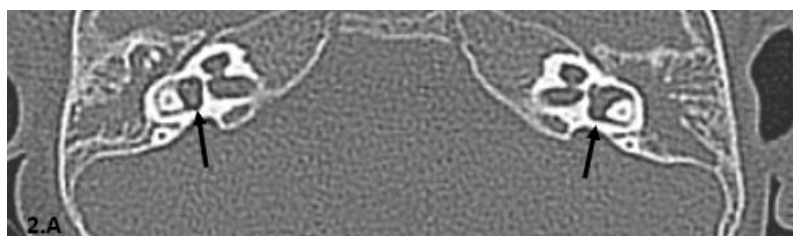


Figure 2. A: Axial CT, bone window view revealed bilateral normal vestibules (black arrows).

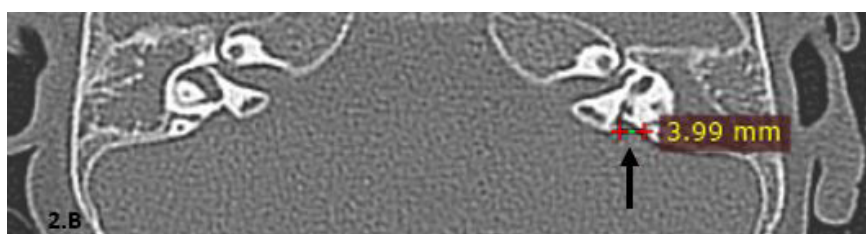


Figure 2. B: Axial CT, bone window view revealed a dilated vestibular aqueduct on the left side (black arrow). Normal diameter less than 1.5 mm.

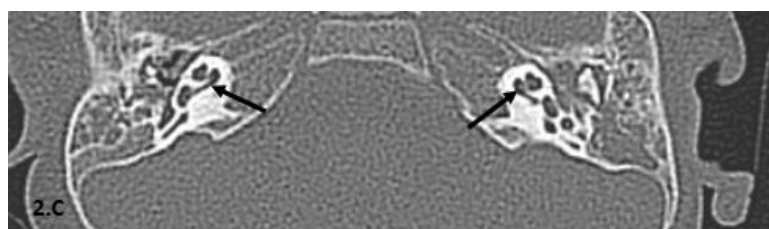


Figure 2. C: Axial CT, bone window view revealed bilateral average cochlear morphology with normal cochlear turns.

Case 3:

A female patient 1.8 years old suffered from prelingual profound Sensorineural hearing loss. MSCT showed multiple congenital anomalies of the petrous bones bilaterally (Fig.3) in the form of mild cochlear hypoplasia, bilateral cystic dilatation of the vestibules, bilateral external auditory canal bony atresia, improper alignment of the ossicular chains, normal Caliber of the vestibular aqueduct and normal both internal auditory canals. According to CT findings, this case was a good candidate for cochlear implantation, and surgery was done successfully.

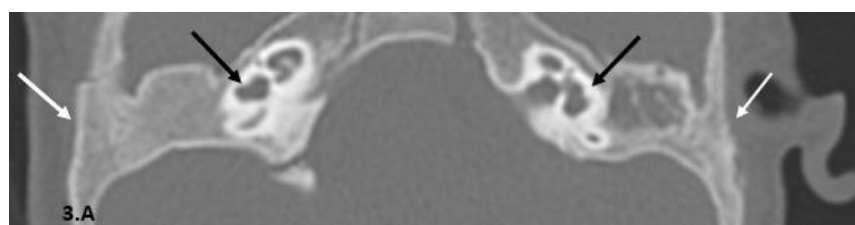


Figure 3. A: Axial CT view, bone window revealed bilateral external auditory canal bony atresia (white arrows). bilateral cystic dilatation of the vestibules (black arrows).

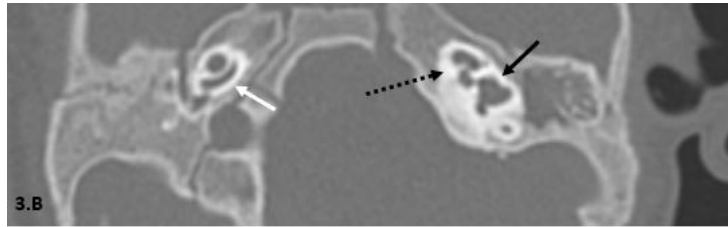


Figure 3. B: Axial CT view, bone window revealed left side cystic vestibule (black solid arrow), right cochlea shows 1.5 turns only instead of 2.5 turns (white arrow), left side dilated cystic apex of the cochlea (dashed black arrow).

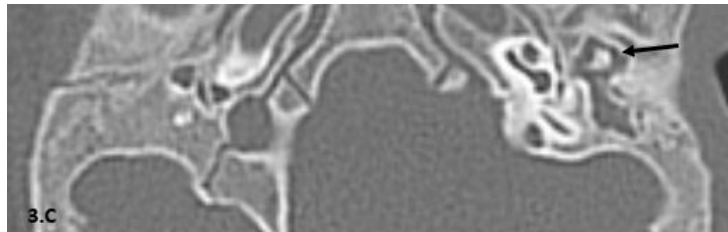


Figure 3. C: Axial CT view, bone window revealed improper alignment of the ossicular chain (black arrow).

Case 4:

A 3-year-old female child presented with post-lingual severe to profound SNHL. The patient had past history of meningitis. MSCT revealed completely normal inner ear structures, both internal acoustic canals, both cochlea & both vestibules (Fig.4). According to CT findings, this case was a good candidate for cochlear implantation, and surgery was done successfully.

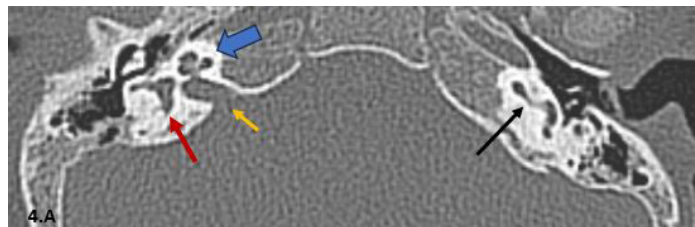


Figure 4. A: Axial CT view, bone window revealed normal vestibular morphology (red arrow), normal cochlear turns (blue arrow), average IAC diameter (yellow arrow), and normal basal cochlear turn (black arrow).

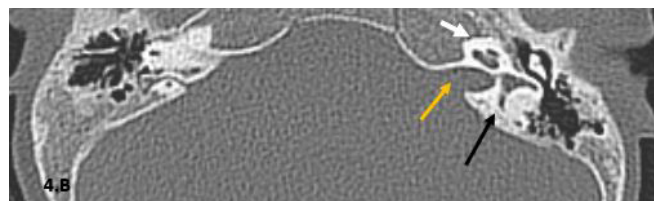


Figure 4. B: Axial CT view, bone window revealed normal vestibular morphology (black arrow), and average IAC diameter (yellow arrow).

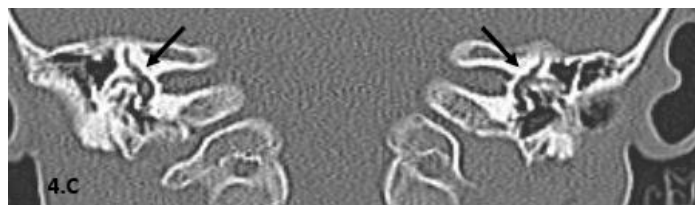

Figure 4. C: coronal CT view, bone window revealed normal bilateral SCCs (black arrows).

Case 5:

A 20-year-old female presented with post-lingual severe to profound SNHL. The patient had past history of Trauma. MSCT revealed normal both bony labyrinths, bilateral hemotympanum, longitudinally oriented left temporal bone fracture, not disrupting the left ossicular chain, longitudinally oriented right temporal bone fracture, disrupting the right ossicular chain associated with right include-malleal dislocation (Fig.5). This case has been considered as contraindication for implantation surgery as it has bilateral longitudinal fractures (postponed for fear of affection of the cochlear nerve which, if true, means that the operation is non-useful).

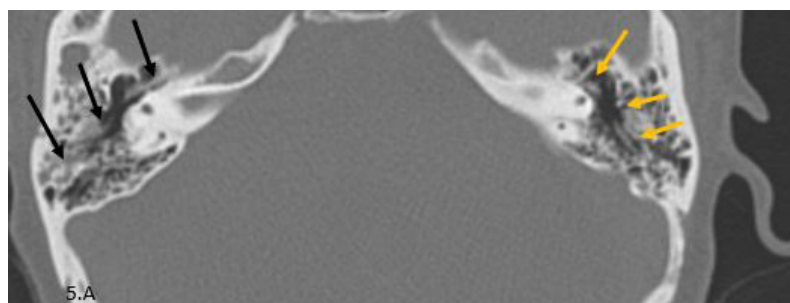


Figure 5. A: Axial CT view, bone window revealed a longitudinal right fracture of the petrous bone with the fracture line demonstrated by the arrows (black arrows), left petrous bone longitudinal fracture (yellow arrows).

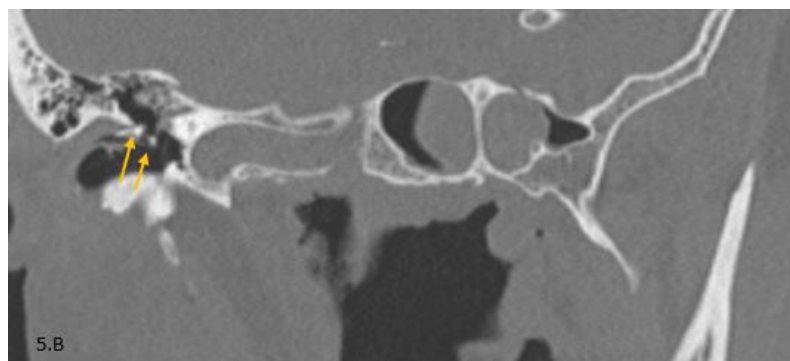


Figure 5. B: right coronal oblique CT view, bone window revealed disruption of the ossicular chain (yellow arrows).




Figure 5. C: Axial CT view, bone window revealed bilateral hemotympanum of the middle ear and mastoid air cells (black arrows)

Case 6:

A 2-year-old female presented with pre-lingual severe to profound SNHL. MSCT revealed normal inner ear structures, hypoplasia of the left middle ear cavity, complete agenesia of the left external ear and left mastoid air cells, and absent left ossicular chain (Fig.6). According to CT finding, this case was a good candidate for cochlear implantation and surgery was done successfully.

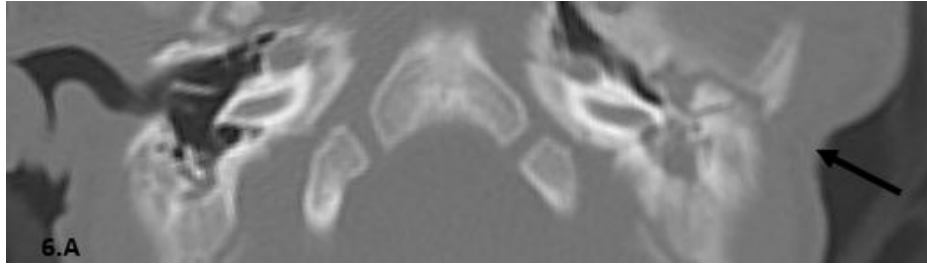


Figure 6. A: Axial CT view, bone window revealed left EAC atresia (black arrow).

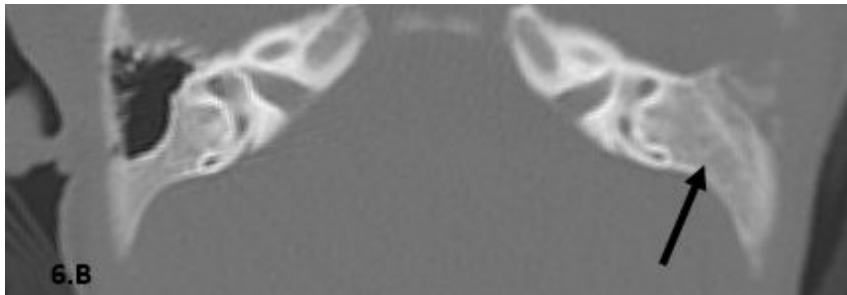


Figure 6. B: Axial CT view, bone window revealed agenesia of the left mastoid air cells (black arrow).

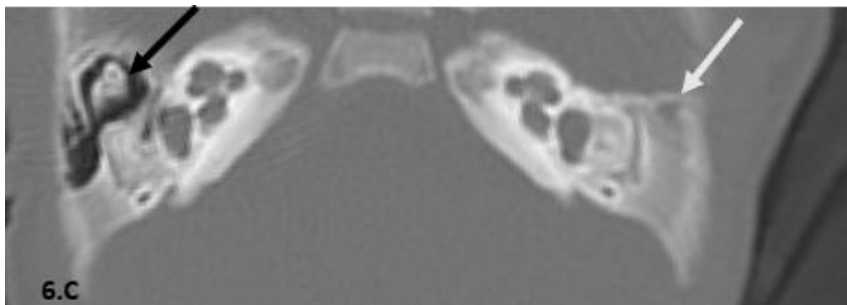


Figure 6. C: Axial CT view, bone window revealed normal right middle ear cavity and ossicular chains (black arrow), left side absent middle ear cavity (white arrow).

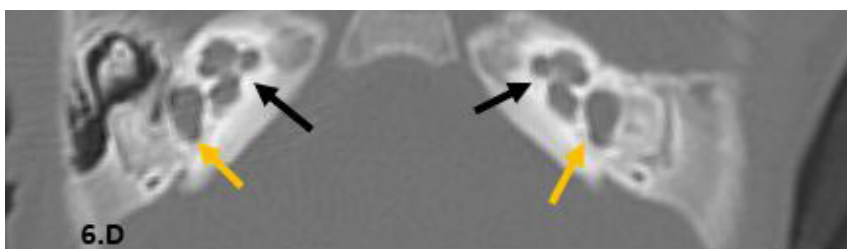


Figure 6.D: Axial CT view, bone window revealed normal bilateral cochlear morphology (black arrow), and both vestibules are within normal (yellow arrows).

Case 7:

A male patient 16 years old with post-lingual profound Sensorineural hearing loss. The patient had a past history of meningitis. MSCT revealed diffusely increased bone densities around inner and middle ear components with the normal configuration of the inner ear structures (Fig. 7), findings suggestive of bilateral labyrinthitis ossificans. This case has been considered a contra-indication for cochlear implantation surgery, where the deposition of calcium within the labyrinthine canal affects the insertion of the wire during the cochlear implantation operation.

Picture suggestive of bilateral Labyrinthitis ossificans.

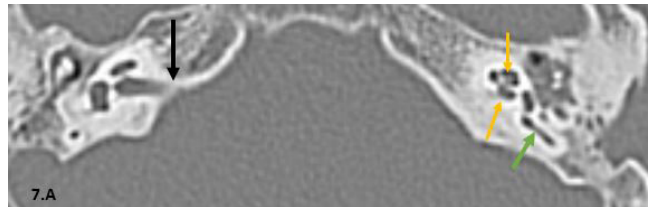


Figure 7. A: Axial CT view, bone window revealed intra cochlear multiple foci of bright hyperdense areas which are suspected to be foci of calcifications (yellow arrows), SCC internal foci of calcifications (green arrow), normal IAC diameter (black arrow).

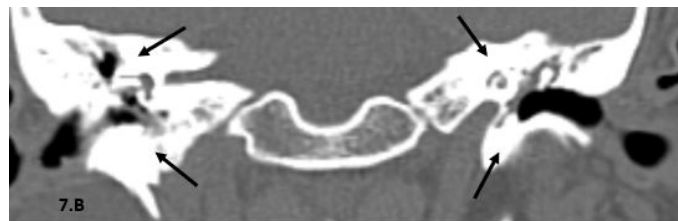

Figure 7. B: coronal CT view, bone window revealed bilaterally increased bone densities around inner and middle ear components (black arrows).

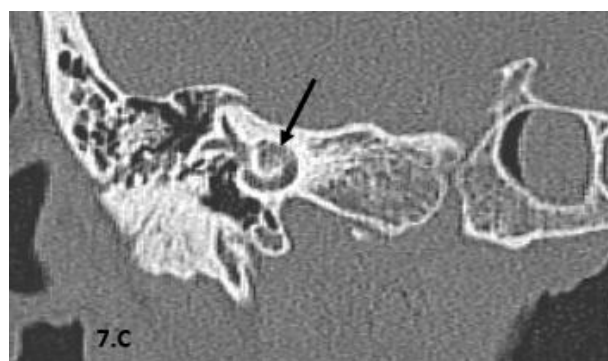


Figure 7. C: right coronal oblique CT view, bone window revealed normal vestibule and normal SCCs morphology (black arrow).

Case 8:

A male patient 2.8 years old with pre-lingual severe Sensorineural hearing loss. MSCT showed completely normal inner ear structures, normal both IAC, both cochleae, and vestibules (Fig.8). The cause of SNHL, in this case, is likely on the microscopic level, in the form of affection of the hair cells inside the cochlea. According to CT findings, this case was a good candidate for cochlear implantation, and surgery was done successfully.

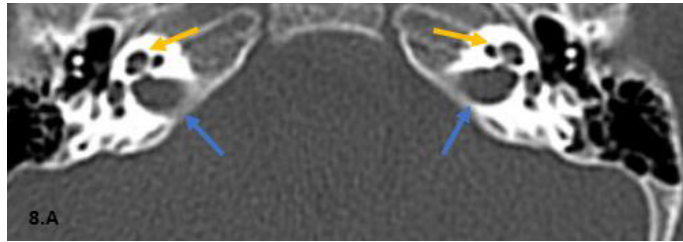


Figure 8. A: axial CT view revealed normal bilateral cochlear morphology (yellow arrows), and normal bilateral diameter of IACs (blue arrows).

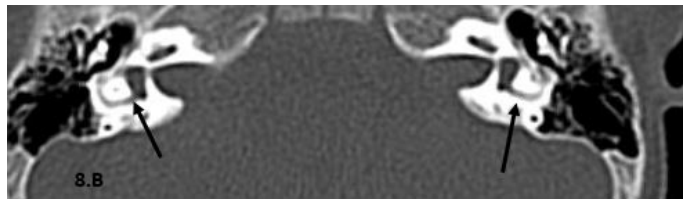


Figure 8. B: axial CT view revealed normal bilateral vestibules (black arrows).

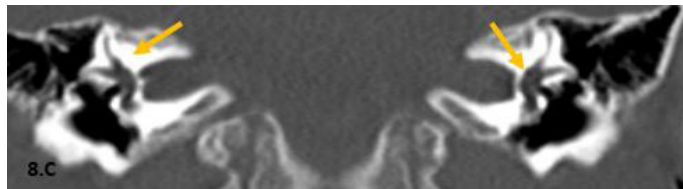


Figure 8. C: coronal, bone window CT view revealed normal bilateral vestibules and SCCs (yellow arrows).

Discussion:

Cochlear implantation surgical procedure is considered the surgical procedure of choice for the management of severe to profound SNHL. It has highly increased speech perception in children with SNHL [9].

Cochlear implant candidacy and outcomes have increased which reflects technological advancement, early detection, and better gathering between the surgical procedure and the follow-up care. Children and adults with a wide variable range of hearing losses can now benefit from cochlear implantation procedures [10].

Cochlear implant devices are advised for children from the age of 12 months with no upper limit [11].

Various types of cochlear implant devices are available which are multi-channel array intracochlear devices [2].

Preoperative delineation of the morphological anatomy of petrous bone is crucial for the decision whether to perform cochlear implantation procedure or not, guiding the surgical techniques and device programming by audiologists. Preoperative CT imaging aims to detect and locate inner ear abnormalities and other morphological variabilities that affect a patient's candidacy, ear selection, surgical technique, and prognosis [2].

The purpose of this study was to detect the diagnostic capability of multi-detector CT in pre-operative work-ups for pre-lingual and post-lingual cochlear implant

candidates.

All cases (30 cases) underwent pre-operative multi-detector CT assessment of both petrous bones to figure out the anatomical configuration and the morphological variations which help in the detection of the anomaly, if present, and to make the proper decision whether attempting cochlear implantation procedure or not and to help the clinician make better choice of the suitable surgical technique.

In our study, patients with congenital inner ear malformations are presented as pre-lingual SNHL. Many cases diagnosed clinically as post-meningitic labyrinthitis in our study (20 cases) show normal inner ear CT findings, representing 66.7% of cases, where most of them are presented as pre-lingual SNHL (13 patients) and the rest (7 patients) as post-lingual SNHL according to the onset of their affection with meningitis.

In our current study, we followed Lane et al., (2006) [12], who declared that applying a reconstruction with sagittal oblique with many angles had solved the obstacle of volume averaging effect at semicircular canals imaging with accurate detection of vestibular aqueduct dilatation abnormality. We found also that 3D reconstruction of MSCT helps better delineate of the anatomical abnormalities involving the vestibular aqueducts.

In this study, as done by Connor et al. (2009) [13], a double-oblique Para-coronal reformatted image of the cochlea was obtained. This was rendered with a maximum intensity projection.

We support the protocol declared by Joshi et al., (2012) [8], who revealed that the most important pre-surgical implantation CT checklist includes: presence, patency, and morphological anatomy of the cochlea, vestibule and SCC status, diameter of vestibular aqueduct, internal auditory canal morphology, patency of middle ear pathway, mastoid air cells pneumatization and jugular bulb position.

In the present study, many patients complaining of SNHL had normal inner ear anatomy on CT (around 70%), with congenital and acquired inner ear abnormalities detected only in 30 % of the patients. This agreed with Haung et al., (2012) [14], who found that SNHL is usually resulting from isolated anomalies on the microscopic or cellular levels that do not disturb the configuration of the membranous inner ear or bony otic capsule (such as cases of post-meningitic labyrinthitis).

In the present study, we found that the most common inner ear abnormality in children was vestibular aqueduct dilatation. The same prevalence was found by Haung et al., (2012) [14] and Phillips et al., (2012) [15]. In contrast to, Aldhafeeri et al., (2016) [16], who said that both vestibular aqueduct dilatation and semicircular canal dysplasia were the most common inner ear anomalies.

As detected by Morzaria et al., (2004) [17], who found that labyrinthitis/ meningitis was the most common aetiology of acquired bilateral SNHL. In the present study, the 8 patients presented to us with post-lingual hearing loss, 7 of them were diagnosed as post-meningitic labyrinthitis, also all prelingual patients with SNHL showing normal inner ear morphology gave a history of previous meningitis.

In our study, we found that the most common causes of SNHL were acquired aetiologies (representing 73.3% of cases), followed by congenital aetiologies (26.7%). This didn't match with McClay et al., (2008) [18], who declared that the described sensorineural hearing loss in children was mainly of genetic aetiologies in about half of their sample (170 patients) and acquired and other unknown aetiologies represent the other half of their sample.

Multi-slice CT was used in the present study as the main modality for pre-operative evaluation of cochlear implantation candidates while, Mackeith et al., (2012) [19], has reported that combined MRI and multi-detector CT was preferred as an assessment of the cochlear nerve abnormalities like its absence or labyrinthine fibrosis in its early stages (considered post-meningitic sequelae) can be done by MRI. CT also can detect cochlear nerve abnormalities by measuring the IAC diameter which if less than 4 mm indicates cochlear nerve hypoplasia and if the IAC was around 2 mm, this indicates mostly its absence.

In our study, from the 30 patients diagnosed with SNHL included in our study, only 8 patients (26.6%) (prelingual) showed congenital abnormalities of their inner ear's structures like Michele anomaly, Incomplete partition type II, common cavity, cystic vestibule, and vestibular aqueduct dilatation. This agrees with Gupta et al. (2009) [20], who declared that inner ear congenital abnormalities are relatively rare, that is why, they only noticed on multi-Slice CT imaging in a range of twenty

percent of patients with congenital SNHL.

In our thesis, 4 cases are diagnosed with vestibular aqueduct abnormalities and underwent cochlear implantation successfully, which agrees with Hall et al., (2019) [21], who found that large vestibular aqueduct syndrome (LVAS) cases are considered the candidates of choice for cochlear implantation surgical procedure.

In the present study, one case has been diagnosed as incomplete partition type II and managed successfully in agreement with Sennaroglu et al (2006) [22], who reported that surgical cochlear implantation is possible in patients with Incomplete partition types I / II, common cavity and large vestibular aqueduct syndrome.

Many future research studies are highly recommended to be done on larger groups of cochlear implant candidates to increase the possibility of coverage of a wider range of inner ear abnormalities according to preoperative CT assessment.

Conclusions:

MSCT is the most effective diagnostic modality for assessment of cochlear implant candidates. It is now performed routinely as a preoperative evaluation before cochlear implantation surgery. This could be attributed to the advantages of MSCT, including short scan time, low cost, and no need for anaesthesia. **R**

List of abbreviations:

MSCT: Multi-Slice Computed tomography.

SNHL: Sensory Neural Hearing Loss.

E.N.T: Ear, Nose And throat.

SCC: Semi-Circular Canal.

IAC: Internal Auditory Canal.

mAs: Milli Ampere.

kVp: Kilovoltage Peak.

IP: Incomplete partition.

Fig: Figure.

LVAS: large vestibular aqueduct syndrome.

REFERENCES

- Barbosa, Felix, Ribeiro, et al. Profile of patients assessed for cochlear implants. *Braz J Otorhinolaryngol* 2014; 80(4): 305-10.
- Young, Ryan, and Young. Preoperative imaging of sensorineural hearing loss in pediatric candidates for cochlear implantation. *Radiographics* 2014; 34(5): E1.
- Vlastarakos, Nikolopoulos, Pappas, et al. Cochlear implantation update: contemporary preoperative imaging and future prospects - the dual modality approach as a standard of care. *Expert Rev Med Devices* 2010; 7(4): 555-67.
- Park, Amoodi, Kuthubutheen, et al. Predictors of round window accessibility for adult cochlear implantation based on pre-operative CT scan: a prospective observational study. *J Otolaryngol Head Neck Surg* 2015; 44: 20.
- Michele B, and Barry E. Imaging of Hearing Loss. *Otolaryngologic Clinics of North America* 2008; 41, 157-178.
- Fatterpekar GM, Doshi AH, Dugar M, et al. Role of 3D CT in the evaluation of the temporal bone. *Radiographics*. 2006 Oct;26 Suppl 1:S117-32. doi: 10.1148/rg.26si065502. PMID: 17050510.
- Agha, Eid, Fathi, et al. Congenital hearing loss. Is CT enough? *Alexandria Journal of Medicine*. Volume 50, Issue 2, June 2014, Pages 113-121
- Joshi VM, Navlekar SK, Kishore GR, et al. CT and MR imaging of the inner ear and brain in children with congenital sensorineural hearing loss. *Radiographics*. 2012 May-Jun;32(3):683-98. doi: 10.1148/rg.323115073. PMID: 22582354.
- Kang DH, Lee MJ, Lee KY, et al. Prediction of Cochlear Implant Outcomes in Patients with Prelingual Deafness. *Clin Exp Otorhinolaryngol*. 2016 Sep;9(3):220-5. doi: 10.21053/ceo.2015.01487. Epub 2016 Jun 25. PMID: 27337951; PMCID: PMC4996110.
- Skinner MW, Ketten DR, Holden LK, et al. CT-derived estimation of cochlear morphology and electrode array position in relation to word recognition in aNucleus-22 recipients. *Journal of the Association for Research in Otolaryngol* 2002; 1;3(3):332-50.

11. Odges, A. V. & Balkany, T. J. Cochlear implants for sensorineural hearing loss. *Hospital Physician* 2002; 38(10), 22-32.
12. Lane JL, Lindell EP., Witte RJ., et al. Middle and inner ear: Improved depiction with multiplanar reconstruction of volumetric CT data. *Radiographies* 2006; 26:115-124.
13. Connor SEG, Bell DJ, O’Gorman R, et al. CT &MR imaging cochlear distance measurements may predict cochlear implant length required for a 360 insertion. *American Journal of neuroradiol* 2009; 30(7), 1425-1430.
14. Haung BY., Zadanski C. and Castillo M. Pediatric sensorineural-hearing loss, part 1: Practical Aspects for Neuro-radiologists. *Am J Neuroradiol*; 2012; 33(2):211-217.
15. Phillips GS, LoGerfo SE, Richardson ML, et al. Interactive Web-based learning module on CT of the temporal bone: anatomy and pathology. *Radiographies* 2012; 32(3), E85-E105.
16. Ahmad M. Aldhafeeri, MD, KSUF and Abdulrahman A. Alsanosi, MD, KSUF: Prevalence of inner ear anomalies among cochlear implant candidates. *Saudi Med J*. Oct 2016;37(10): 1096–1100.
17. Morzaria S, Westerberg BD and Kozak FK. Systematic review of the etiology of bilateral sensorineural hearing loss in children. *Int J Pediatr Otorhino-laryngol.* 2004; 68:1193-98.
18. McClay J E, Booth T N, Parry D A, et al. Evaluation of pediatric Sensorineural hearing loss with magnetic resonance imaging. *Archives of otolaryngol- Head &neck Surg* 2008; 146:180-190.
19. Mackeith S1, Joy R, Robinson P, and Hajioff D: Pre-operative imaging for cochlear implantation: magnetic resonance imaging, computed tomography, or both? *Cochlear Implants Int.* 2012; Aug 13(3):133-6.
20. Gupta SS., Maheshwari SR., Kirtane MV, et al. Pictorial review of MRI/CT scan in congenital temporal bone anomalies, in patients for cochlear implant. *Indian J Radiol Imaging* 2009; 19(2): 99-106.
21. Hall Andrew C, Kenway Bruno, Sanli Halit, et al. Cochlear Implant Outcomes in Large Vestibular Aqueduct Syndrome—Should We Provide Cochlear Implants Earlier? *Otology & Neurotology*: September 2019 - Volume 40 - Issue 8 - p e769-e773. doi: 10.1097/MAO.0000000000002314.
22. Sennaroglu L, Sarac S and Ergin T. Surgical Results of Cochlear Implantation in Malformed Cochlea. *Otology & Neurotology*: August 2006 - Volume 27 - Issue 5 - p 615-623. doi: 10.1097/01.mao.0000224090.94882.b4.



READY - MADE
CITATION

Amal I A. Othman, Fatma S. Mohammed, Mostafa S A. Elghobashy, Ali H. Ali. Impact of MSCT in pre-operative assessment of temporal bone in pre-lingual and post-lingual SNHL prior to cochlear implantation. *Hell J Radiol* 2024; 9(1): 11-25.